

# Mural Unicystic Ameloblastoma Crossing the Midline: A Rare Case Report

Ameloblastoma Uniquístico Mural Traspasando la Línea Mediana:  
Reporte de un Caso Infrecuente

Kiran Kumar, K. R.; Giju Baby George; Sheeba Padiyath & Rupak, S.

---

KUMAR KUMAR, K. R.; GEORGE, G. B.; PADIYATH, S. & RUPAK, S. Mural unicystic ameloblastoma crossing the midline: a rare case report. *Int. J. Odontostomat.*, 6(1):97-103, 2012.

**ABSTRACT:** Ameloblastoma is a benign odontogenic neoplasm which frequently affects the mandible. The term ameloblastoma includes several clinico-radiological and histological types. Apart from the most commonly encountered clinico-pathologic models there are few variants, whose biological profile is unknown or not elicited. The reason for lack of understanding is the scarcity of case report published in the literature. Among the types, unicystic ameloblastoma is the least encountered either it presents as unilocular or multilocular radiolucency, but peculiar radiographic presentation of multilocular radiolucency in posterior mandible with unilocular radiographic appearance crossing the midline is extremely rare, which has not been reported yet. Here we report a distinctive case of mural unicystic ameloblastoma of mandible in a 17-year-old-girl with the radiographic presentation as mentioned above.

**KEY WORDS:** ameloblastoma, luminal, odontogenic tumors, unicystic ameloblastoma.

---

## INTRODUCTION

Many benign lesions cause mandibular swellings and these can be divided into odontogenic and nonodontogenic origin (Kahairi *et al.*, 2008). The most common tumor of odontogenic origin is ameloblastoma which develops from epithelial cellular elements and dental tissues in their various phases of development. More than 80% of all ameloblastomas are solid or multicystic variants, with unicystic ameloblastoma being an important clinicopathologic form of ameloblastoma and occupying the remaining 20% of the cases along with peripheral ameloblastoma. Robinson and Martinez were the first to recognize unicystic ameloblastoma as a distinct entity in 1977 (Neville *et al.*, 2002; Philipsen, 1998; Melrose, 1999; Ackermann *et al.*, 1998).

Unicystic Ameloblastoma (UCA) is the most common term used to designate its different pathological entities. Sometimes these can present as a multilocular radiolucency which makes use of the term 'cystic ameloblastoma' more appropriate.

However some authors still have the notion that cystic ameloblastomas can have a 'true' clinically multicystic pattern is arguable, and contend with the use of the term 'unicystic ameloblastoma' (Reichart & Philipsen, 2004; Eversole *et al.*, 1984).

Though, the fact that the term unicystic would imply a unilocular radiographic appearance, the lesion can sometimes have a multilocular radiographic appearance (Paikkatt *et al.*, 2007). But peculiar radiographic presentation of multilocular radiolucency with unilocular radiographic appearance in the mandible is very unusual which is not encountered in the literature and such presentation makes a diagnostic challenge to the oral radiologist in arriving at correct pre-operative diagnosis.

Here we report a distinctive case of unicystic ameloblastoma of mandible with unusual multilocular radiolucent pattern in the posterior mandible with a unilocular radiolucency anteriorly crossing the midline, which is a rarity in the literature of UCA.

## CASE REPORT

A 17-year-old-girl reported to Department of Oral Medicine and Radiology with a chief complaint of painful swelling over the left lower jaw of 2 months duration. Swelling was gradual in onset, slowly increased to present size with no history of paresthesia or surface changes. Past Medical, Dental and Family history were non contributory. On general examination, she was moderately built and nourished with normal vital signs.

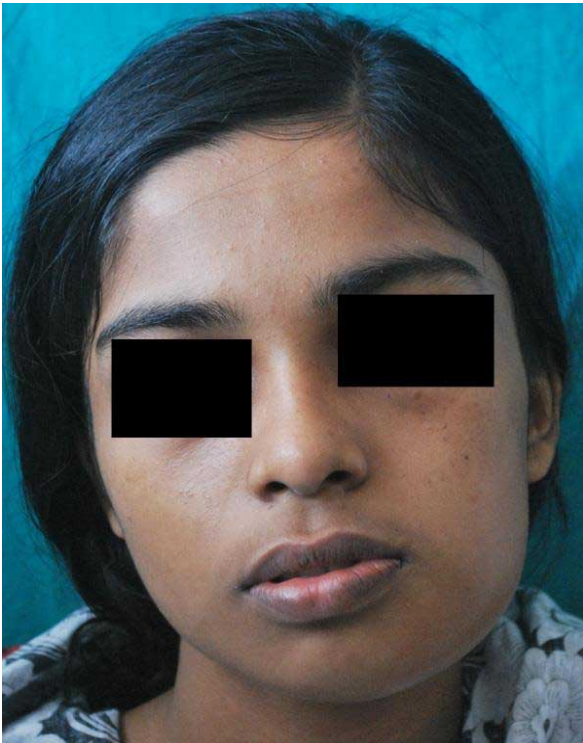

Fig. 1A. Clinical photograph shows extra oral swelling in the left mandibular region.

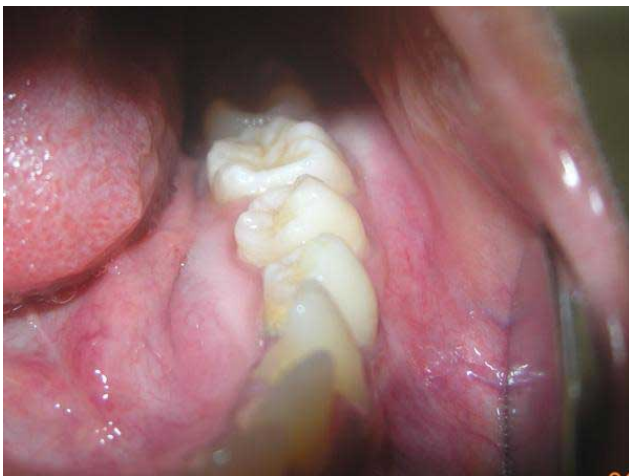

Fig. 1B. Clinical photograph shows intra oral swelling in 34, 35 and 36 region.

Extra oral examination (Fig. 1A) revealed a well defined round solitary swelling over the left body of mandible of 7x6 cm extending from corner of mouth to angle of mandible and supero-inferiorly from level of ala-tragus line to lower body of mandible. Skin over swelling appears normal with no surface changes. Swelling was tender, bony hard in consistency, non reducible and non compressible with no local rise in temperature. Enlarged left solitary submandibular lymph node was soft, mobile and non tender. Intra oral examination (Fig. 1B) revealed a well defined solitary oval swelling of 3x2 cm on the lingual aspect of 34, 35 and 36, extending from distal aspect of 34 to the mesial aspect of 36. Swelling was tender, bony hard with lack of compressibility and reducibility. Buccal and lingual cortical plate expansion was noticed in relation to 34, 35, 36 and 37. Buccal aspect of 3.6 demonstrated egg shell crackling with grade I mobility and 34, 35, 36 & 37 were non- vital.

Intra oral periapical radiograph of 36 showed a well defined multilocular radiolucency in the apical region of 35, 36, and 37 with root resorption of 36. Lateral mandibular occlusal radiograph (Fig. 2A) revealed a well defined multilocular radiolucency extending from distal aspect of 32 to mesial aspect of 38 with bicortical expansion and resorption of lingual cortex. Panoramic radiograph (Fig. 2B) showed a well defined multilocular radiolucency with sclerotic border extending from mesial aspect of 36 till distal aspect of 37 with a large unilocular radiolucency of 6x4 cm extending anteriorly and crossing midline. Sagittal CT scan (Fig. 3A) demonstrated a well defined multilocular radiolucency in the left body of mandible, with root resorption of 36. Coronal section (Fig. 3B) showed a well defined unilocular radiolucency with sclerotic border in the anterior mandible. Surface rendered 3D image (Fig. 3C) revealed perforation of buccal and lingual cortices of the left body of mandible with multiple septa.

We arrived at a radiological diagnosis of ameloblastoma based on clinical and radiographic findings. Incisional biopsy specimen taken from the lingual aspect of 34-35 region was subjected to histopathologic examination, which revealed areas of primitive epithelial lining (Fig. 4A) with focal areas of mural ameloblastomatous proliferation into the connective tissue stroma. Connective tissue also showed areas of ameloblastomatous islands (Fig. 4B) with reversal of polarity of peripheral columnar basal cells and central stellate reticulum like cells. Some follicles showed cystic degeneration and connective tissue appears to be myxomatous in few areas.

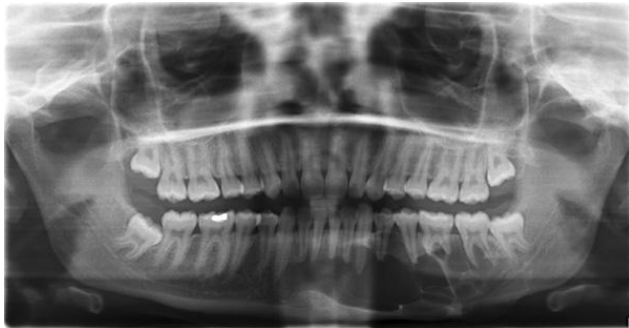


Fig. 2A. Panoramic radiograph shows multilocular radiolucency in left body of mandible with anterior unilocular radiolucency crossing midline.

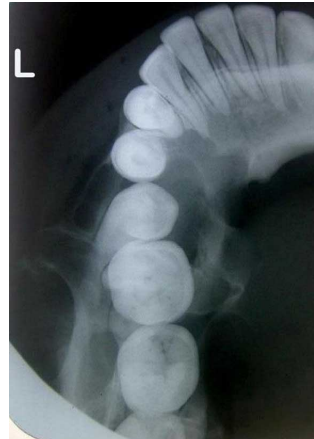


Fig. 2B. Lateral mandibular occlusal radiograph shows multilocular radiolucency in left body of mandible with bicortical expansion & resorption of lingual cortex.

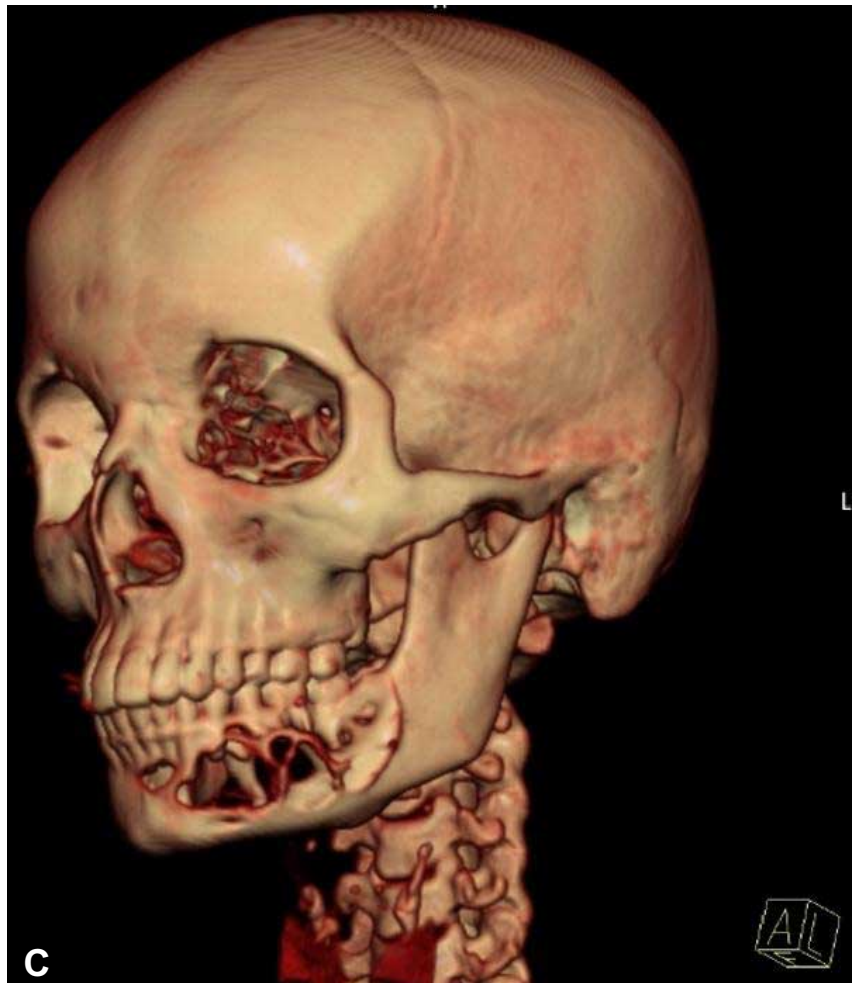
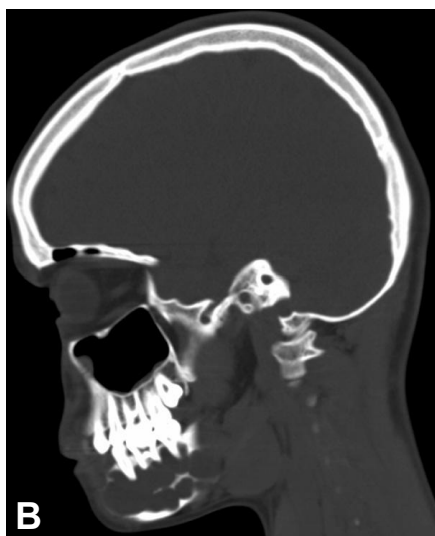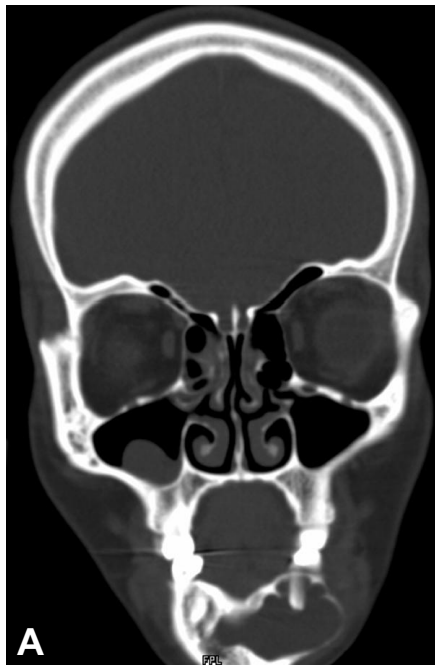


Fig. 3A. Sagittal CT scan shows a well defined multilocular radiolucency in the left body of mandible with root resorption of 36.

Fig. 3B. Coronal CT scan shows a well defined unilocular radiolucency with sclerotic border in the anterior mandible.

Fig. 3C. Surface rendered 3D image shows perforation of buccal and lingual cortices of the left body of mandible with multiple septa.

Histopathologic report was confirmative of mural unicystic ameloblastoma. Surgical excision along with chemical cauterization with Carnoy's solution was done under general anesthesia. Excisional biopsy specimen also revealed mural unicystic ameloblastoma and post operative 6 months follow up was uneventful.

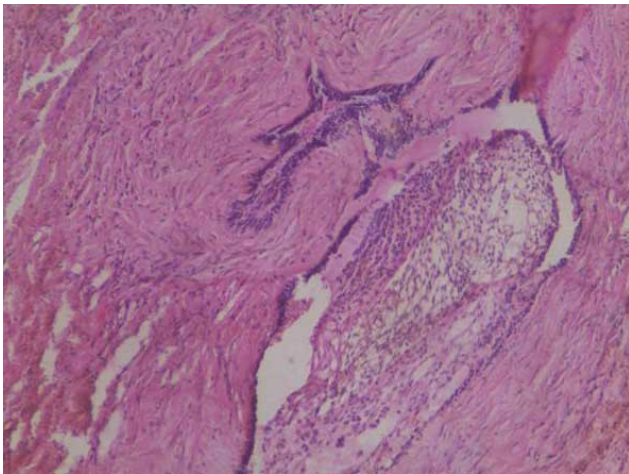


Fig. 4A. H & E stained section shows primitive epithelial lining with focal areas of mural ameloblastomatous proliferation into the connective tissue stroma (10 X).

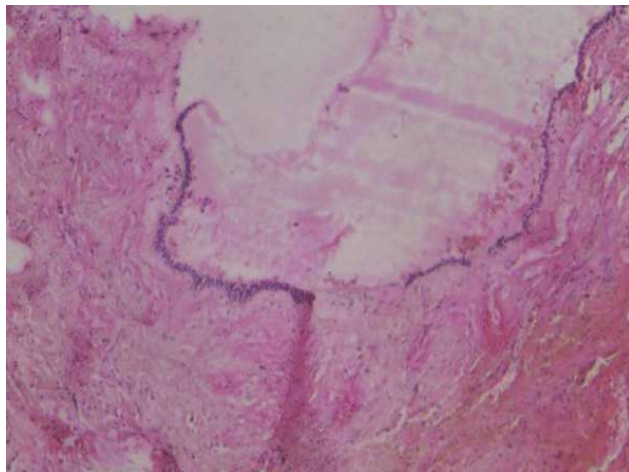


Fig. 4B. H & E stained section shows areas of ameloblastomatous islands with reversal of polarity of peripheral columnar basal cells and central stellate reticulum like cells (10 X).

## DISCUSSION

Unicystic Ameloblastoma is a rare type of ameloblastoma, accounting for about 6% of ameloblastomas, which is most often seen in young patients with 50% of such tumors diagnosed during

the second decade of life (Roos *et al.*, 1994). Compared to multicystic ameloblastoma, UCA occurs more commonly at younger age as in our case. It most commonly occurs in posterior mandible followed by parasymphysis region, anterior maxilla and posterior maxilla. The age is considerably lower and ranges from 19 to 27 years (Reichart & Philipsen). In our case, the lesion occurred in the body of mandible in 17 year old, which is similar to the studies reported by Ackermann *et al.* and Paikkatt *et al.*

UCA is usually asymptomatic, although a large tumour may cause painless swelling of the jaws with facial asymmetry. Small lesions are sometimes discovered more on routine radiographic screening examinations or as a result of local effects like tooth mobility, occlusal alterations and failure of eruption of teeth produced by the tumour. Mucosal ulceration is rare, but may be caused by continued growth of the tumour (Paikkatt *et al.*; Roos *et al.*). Although the histology suggests that UCAs follow a biologically low grade course, they may often behave clinically as biologically aggressive tumors. This is supported by the high incidence of cortical perforation, tooth resorption, lesion size, and bony destruction (Ackermann *et al.*). These findings were evident in our case study and the similar findings have been reported by Paikkatt *et al.* and Roos *et al.* The clinical and radiographic findings in most cases of unicystic ameloblastoma suggest that the lesion is an odontogenic cyst, particularly dentigerous cyst (Roos *et al.*). However few are not associated with impacted teeth which are called non dentigerous variant. The mean age of nonimpacted tooth related cystic ameloblastoma was 35 years in comparison to 16.5 years for the impacted tooth related variant (Ackermann *et al.*). Most of the UCAs are associated with an impacted tooth, the mandibular third molar being involved most often. But our case was of non dentigerous variant. These findings correlate with those reported by Philipsen *et al.* and Ackermann *et al.*

The pathogenesis of cystic ameloblastomas remains obscure. Whether UCA originates de novo as a neoplasm or whether it is a result of neoplastic transformation of non-neoplastic cyst epithelium has long been debated. Both mechanisms probably occur, but proof of which of the above is involved in an individual patient is virtually impossible to obtain. Some investigators believe that UCA arises from pre-existing odontogenic cysts, in particular a dentigerous cyst, while others maintain that it arises *de novo*. The reason why some ameloblastomas become completely cystic

may be related to epithelial dysadhesion (e.g. defective desmosomes) or, more likely, to the intrinsic production of proteinases (e.g. metalloproteinases, serine proteinases); enzymes that normally degrade the central zone of the enamel organ after tooth development (Rosenstein *et al.*, 2001). Three pathogenic mechanisms for the evolution of UCA were proposed by Leider *et al.* (1985). Robinson & Martinez (1997) argued that as the epithelium of odontogenic cysts and ameloblastomas have a common ancestry, a transition from a non-neoplastic to a neoplastic one could be possible, even though it occurs infrequently (Ackermann *et al.*).

The radiographic appearance of UCAs has been divided into 2 main patterns: unilocular and multilocular and these have clear preponderance for the unilocular pattern. This preponderance is predominantly marked for the dentigerous variant, where the unilocular to multilocular ratio is 4.3:1 and for the nondentigerous type, this ratio is 1.1:1 (Eversole *et al.*). The involved teeth show varying degrees of root resorption (Philipsen & Reichart). Eversole *et al.* identified predominant radiographical patterns for UCA: unilocular, scalloped, macromultilocular, pericoronal, interradiolar, or periapical expansile radiolucencies (Paikkatt *et al.*). Our case study had a peculiar radiographic presentation of multilocular radiolucency in the posterior body of the mandible with unilocular radiolucency crossing the midline; such case report has not been encountered in the literature. This makes our case study a unique report in the literature of UCA. The possible explanation for such occurrence may be solid proliferation of ameloblastoma in posterior mandible might have been from mural proliferation of odontogenic tumor epithelial cells of unicystic ameloblastoma in anterior mandible. Other possibilities may be that two lesions are completely separate lesions or they may be due to same lesion showing skip bone involvement, or both might have been solid ameloblastomas with anterior lesion undergoing cystic degeneration of ameloblastic islands with subsequent fusion of multiple microcysts developing into a unicystic lesion.

The early ameloblastic changes within the cyst wall was first described by Vickers and Gorlin in 1970 and their histologic criteria for the diagnosis of unicystic ameloblastoma includes a cyst lined by ameloblastic epithelium with a tall columnar basal layer, subnuclear vacuoles, reverse polarity of hyperchromatic nucleus and a thin layer of edematous, degenerating stellate reticulum like cells on the surface (Braunshstein *et al.*,

2003). The mural extension into the cystic wall is a frequently seen feature and term mural UCA is used when the thickened lining (either plexiform or follicular) penetrates the adjacent capsular tissue (Philipsen *et al.*). Ackermann *et al.* in their landmark study classified the histological subtypes into three patterns, namely luminal (Type 1), intraluminal (Type 2) and mural patterns (Type 3). According to Philipsen & Reichart classification, UCA has been sub-grouped into four different entities They are luminal (1), luminal and intra luminal (1.2), luminal, intra luminal, and intra mural (1.2.3), luminal and intramural (1.3) types (Eversole *et al.*). The mural variety is seen to be more often associated with the 'nondentigerous' type of these lesions, while the intraluminal proliferations are more than twice as frequent in UCAs of the 'dentigerous' type (Philipsen & Reichart). According to Ackermann *et al.* classification, our case study belongs to Type 3, which was similar to the case reports of Roos *et al.*, Rosenstein *et al.* and Leider *et al.*

A definitive diagnosis of unicystic ameloblastoma can only be done by histological examination of entire lesion and cannot be predicted preoperatively on clinical or radiographic grounds. As preoperative incisional biopsy is not representative of entire lesion it may result in an incorrect classification. Furthermore, the epithelial lining of a UCA is not always uniformly characteristic and often is lined partly by a nonspecific thin epithelium that mimics the dentigerous cyst lining. Thus, true nature of the lesion becomes evident only after enucleation when entire specimen is available for microscopy. With any presumed unicystic ameloblastoma, multiple sections through many levels of specimen are necessary to rule out the possibility of mural invasion of tumor cell (Roos *et al.*).

Several attempts have been made in the past to distinguish the lining of the UCAs from that of odontogenic cysts. However, immunohistochemical markers like lectins (*Ulex europaeus agglutinin I* and *Bandeirea simplicifolia agglutinin I*) and proliferating cells (proliferating cell nuclear antigen and Ki-67) may assist in their differential diagnosis (Li *et al.*, 1995). However, Eversole *et al.* contends that currently unaided histologic assessment for UCA remains the gold standard for diagnosis, because of a variable response of UCA to tissue markers (Paikkatt *et al.*). Histologically, the minimum criteria for diagnosing a lesion as UCA is the demonstration of a single cystic sac lined by odontogenic (ameloblastomatous) epithelium often seen only in focal areas (Konouchi *et al.*, 2006).

Treatment of UCA remains controversial and greatly differs from that of conventional ameloblastoma. Among the types, unicystic ameloblastomas showing mural proliferation are considered invariably aggressive and should be treated in the same manner as solid multicystic ameloblastoma, whereas other variants can be treated conservatively (Reichart & Philipsen; Eversole *et al.*). The age of the patient is another influencing factor related to the choice of the treatment. As UCA tends to affect young adolescent patients, the concern to minimize surgical trauma and permit jaw function and tooth development to proceed reasonably unimpaired (Roos *et al.*). Recurrence is related to the type of initial treatment and to histologic subtypes of UCA, with those invading the fibrous wall having a rate of 35.7%, but others only 6.7% (Li *et al.*, 2002) reported recurrence rates of 3.6% for resection, 30.5% for enucleation alone, 16% for enucleation followed by Carnoy's solution application, and 18% by marsupialization followed by enucleation (where the lesion reduced in size). The unicystic ameloblastoma is set to be less aggressive clinically than the other variants and has a better prognosis (Philipsen & Reichart). The probable reason for a bad prognosis is that the unicystic ameloblastoma is generally cystic,

well localized and surrounded by a fibrous capsule. However, once the tumor has breached the periphery of the capsule, it can infiltrate the surrounding cancellous bone and therefore may behave more aggressively (Roos *et al.*).

## CONCLUSION

Unicystic ameloblastoma, a type of ameloblastoma, too presents with a variety of clinical, radiological and histopathological features. Radiographically, most of ameloblastomas show multilocularity, whereas unilocular ameloblastomas show a single large unilocular radiolucency. Very rarely we come across a case with presentation of both multilocular and unicystic type in same person. According to recent literature, these lesions are more aggressive than previous thought. Hence, it presents as a challenge both for its diagnosis and treatment and consideration should be given to plan a proper treatment. Finally, this case study adds a rarest of the rare case report to the literature of unicystic ameloblastoma.

---

KUMAR KUMAR, K. R.; GEORGE, G. B.; PADIYATH, S. & RUPAK, S. Ameloblastoma uniuquístico mural traspasando la línea mediana: reporte de un caso infrecuente. *Int. J. Odontostomat.*, 6(1):97-103, 2012.

**RESUMEN:** El ameloblastoma es un tumor odontogénico benigno que frecuentemente afecta a la mandíbula. El término ameloblastoma incluye varias características clínico-radiológicas y tipos histológicos. Aparte de los modelos clínico-patológicos que se encuentran con frecuencia existen algunas variantes, cuyo perfil biológico es desconocido o aún no elucidado. La razón de la falta de comprensión es la escasez de informes de casos publicados en la literatura. Entre los tipos, el ameloblastoma uniuquístico es el menos frecuente y puede presentarse como una radiolucidez unilocular o multilocular, pero la peculiar presentación radiográfica de radiolucidez multilocular en el posterior de la mandíbula con aspecto radiográfico unilocular que cruza la línea mediana es extremadamente rara, y aún no se ha reportado. Se presenta un caso de ameloblastoma uniuquístico mural de la mandíbula en una paciente de 17 años con la presentación radiográfica anteriormente descrita.

---

**PALABRAS CLAVE:** ameloblastoma, luminal, tumores odontogénicos, ameloblastoma uniuquístico.

---

## REFERENCES

- Ackermann, G. L.; Altini, M. & Shear, M. The unicystic ameloblastoma: a clinicopathological study of 57 cases. *J. Oral Pathol.*, 17(9-10):541-6, 1988.
- Braunshtein, E.; Vered, M.; Taicher, S. & Buchner, A. Clear cell odontogenic carcinoma and clear cell ameloblastoma: a single clinicopathologic entity? A new case and comparative analysis of the literature. *J. Oral Maxillofac. Surg.*, 61(9):1004-10, 2003.
- Eversole, L. R.; Leider, A. S. & Strub, D. Radiographic characteristics of cystogenic ameloblastoma. *Oral Surg. Oral Med. Oral Pathol.*, 57(5):572-7, 1984.
- Kahairi, A.; Ahmad, R. L.; Wan Islah, L. & Norra, H. Management of large mandibular ameloblastoma - a case report and literature reviews. *Arch. Orolfac. Sci.*, 3(2):52-5, 2008.

Konouchi, H.; Asaumi, J.; Yanagi, Y.; Hisatomi, M.; Kawai, N.; Matsuzaki, H. & Kishi, K. Usefulness of contrast enhanced-MRI in the diagnosis of unicystic ameloblastoma. *Oral Oncol.*, 42(5):481-6, 2006.

Leider, A. S.; Eversole, L. R. & Barkin, M. E. Cystic ameloblastoma. A clinicopathologic analysis. *Oral Surg. Oral Med. Oral Pathol.*, 60(6):624-30, 1985.

Li, T. J.; Browne, R. M. & Matthews, J. B. Expression of proliferating cell nuclear antigen (PCNA) and Ki-67 in unicystic ameloblastoma. *Histopathology*, 26(3):219-28, 1995.

Li, T.; Wu, Y.; Yu, S. & Yu, G. Clinicopathological features of unicystic ameloblastoma with special reference to its recurrence. *Zhonghua Kou Qiang Yi Xue Za Zhi.*, 37(3):210-2, 2002.

Melrose, R. J. Benign epithelial odontogenic tumors. *Semin. Diagn. Pathol.*, 16(4):271-87, 1999.

Neville, B. W.; Damm, D. D.; Allen, C. M. & Bouquot, J. E. *Odontogenic cysts and tumors. In: Oral and Maxillofacial Pathology.* 2nd edn. St. Louis, W. B. Saunders, 2002. pp.610-8.

Paikkatt, V. J.; Sreedharan, S. & Kannan, V. P. Unicystic ameloblastoma of the maxilla: a case report. *J. Indian Soc. Pedod. Prev. Dent.*, 25(2):106-10, 2007.

Philipsen, H. P. & Reichart, P. A. Unicystic ameloblastoma. A review of 193 cases from the literature. *Oral Oncol.*, 34(5):317-25, 1998.

Reichart, P. A. & Philipsen, H. P. *Odontogenic tumors and allied lesions.* Hanover, Quintessence Publishing Inc., 2004. pp. 69-86.

Robinson, L. & Martinez, M. G. Unicystic ameloblastoma: a prognostically distinct entity. *Cancer*, 40(5):2278-85, 1977.

Roos, R. E.; Raubenheimer, E. J. & van Heerden, W. F. Clinico-pathological study of 30 unicystic ameloblastomas. *J. Dent. Assoc. S. Afr.*, 49(11):559-62, 1994.

Rosenstein, T.; Pogrel, M. A.; Smith, R. A. & Regezi, J. A. Cystic ameloblastoma--behavior and treatment of 21 cases. *J. Oral Maxillofac. Surg.*, 59(11):1311-8, 2001.

Correspondence to:

Dr. Kiran Kumar K R, M.D.S  
Department of Oral Medicine and Radiology  
Mar Baselios Dental College  
Kothamangalam, Ernakulam (Dist)  
PIN-686691, Kerala  
INDIA

Tel: +91-9539631813

Fax: +91-0485-2828745

Email: krksmile@gmail.com

Received: 07-01-2011

Accepted: 22-02-2012