

Superficial Communication Between Ulnar and Median Nerves in the Hand. An Anatomical Study

Comunicación Superficial entre los Nervios Ulnar y Mediano de la Mano. Un Estudio Anatómico

Ivan Dario Quintero^{1,2}; Luis Ernesto Ballesteros¹; Pedro Luis Forero^{3,4}

QUINTERO, I. D.; BALLESTEROS, L. E.; FORERO, P. L. Superficial communication between ulnar and median nerves in the hand. An anatomical study. *Int. J. Morphol.*, 39(6):1516-1520, 2021.

SUMMARY: The objective of this study was to characterize the communication between ulnar and the median nerve in the superficial palmar region from a sample of mestizo-raced population predominant in Latin America. The superficial palmar regions of 53 fresh cadaveric specimens were evaluated, whom of which underwent necropsy procedure at the Institute of Legal Medicine. Dissection was performed by planes until visualizing the presence of the Communicating Branch (CB) between the digital branches of the ulnar nerve (UN) and the median nerve (MN). Qualitative and morphometric evaluation of the CB was carried out. A CB were observed in 82/106 (77.4 %) of the cadaveric specimens studied, of which, 38/53 (71.7 %) were bilateral, 15/53 (28.3 %) unilateral; this being a statistically significant difference ($p < 0.002$). Oblique trajectory of the CB between the fourth and third common digital nerve was observed in 70 (85.4 %) specimens, while the CB with transverse trajectory was found in 7 (8.5 %) regions and in a plexiform form in 5 (6.1 %) cases. The length of the CB was 20.2 ± 5.1 mm and the distances from the upper edge of the flexor retinaculum to the proximal and distal points of the CB were 25 ± 6 mm and 37.4 ± 8.3 mm respectively. The anatomical characteristics of the CB patterns, as well as the morphometric CB findings and their points of reference from the carpal flexor retinaculum, make it possible to delimit a safe area of surgical access in the first-fifth proximal of the palmar region, during the surgical approach of carpal tunnel syndrome.

KEY WORDS Tunnel carpal release; Median nerve; Ulnar nerve.

INTRODUCTION

The communication between the ulnar and median nerves at the superficial palmar level (CUMSP) is also called Berrettini communication. This communicating branch (CB) occurs between the fourth common digital nerve derived from the ulnar nerve (UN) and the third common digital nerve derived from the median nerve (NM). The existence of this anatomical variant may slightly modify the sensory distribution of the third interdigital space. A high incidence of this CB is reported by the majority of authors in a range of 80-96.4 % (Kimura *et al.*, 1983; Meals & Shaner, 1983; Ferrari & Gilbert, 1991; Kolic *et al.*, 1997; Stancic *et al.*, 1999; Don Griot *et al.*, 2000; Olave *et al.*, 2001; Vieria *et al.*, 2002; Loukas *et al.*, 2007).

The CB of oblique trajectory, originating proximal or distally to the inferior margin of the flexor retinaculum of the carpus is the most usual presentation in a range of 70-80 % (Meals & Shaner; Ferrari & Gilbert; Kolic *et al.*; Bas &

Kleinert, 1999; Tagil *et al.*, 2007). The transverse trajectory is reported with an intermediate frequency, in a range of 7-22 % (Ferrari & Gilbert; Kolic *et al.*; Bas & Kleinert; Don Griot *et al.*; Tagil *et al.*). Although the CB is thin and could eventually be confused with a band of connective tissue. Previous reports have not complemented the macroscopic evaluation of the corresponding histological studies.

Of the multiple biometric CB evaluations, it is worth mentioning their length, reported to range from 16 - 9.21 mm (Don Griot *et al.*; Loukas *et al.*) similarly, the distance of their points of origin from the UN and their connection with the third common digital nerve, in relation to the upper edge of the flexor retinaculum, has been reported in previous studies (Don Griot *et al.*; Olave *et al.*; Vieria *et al.*). The CUMSP acquires great importance during incisional or endoscopic surgical procedures of the palm, due to the risk of accidental lesions (Don Griot *et al.*; Loukas *et al.*; Tagil *et al.*).

¹ Division of Human Anatomy, Department of Basic Sciences, School of Medicine, Industrial University of Santander. Bucaramanga, Colombia.

² Division of Orthopedic Surgery, Department of Surgery, School of Medicine, Industrial University of Santander. Bucaramanga, Colombia.

³ Division of Legal Medicine, Department of Pathology, School of Medicine, Industrial University of Santander. Bucaramanga, Colombia.

⁴ National Institute of Legal Medicine and Forensic Sciences, Bucaramanga, Colombia.

The determination of the CUMSP, has been described in other population groups in a detailed manner. Given the scarce information on this CB in the Latin American mestizo population, the purpose of the present study was to characterize the communication between ulnar and the median nerve in the superficial palmar region

MATERIAL AND METHOD

This non-probabilistic and descriptive cross-sectional study determined the frequency and morphological characteristics of the CB in the superficial palmar regions of 53 fresh cadaveric specimens, which underwent necropsy at the Institute of Legal Medicine of Bucaramanga (Colombia). The sample met the following inclusion criteria: male subjects, adults, of the mestizo racial group, without evidence of direct trauma or hand pathology.

In the superficial palmar region, its length was determined from the bistyloid line to the proximal digital fold of the third finger.

With the hand in supination, an incision was made from the distal crease of the wrist to the proximal crease of the ring finger. A meticulous dissection was performed on each of the palmar region layers and subsequently, the fascious cutaneous flaps were harvested laterally and medially. The palmar aponeurosis and the superficial palmar arch were resected and released, allowing the visualization of the digital common nerves of the UN and MN and also the presence or absence of CB between these nerves.

For the determination of the CB trajectory, the Ferrari & Gilbert classification was adopted and modified, joining in a group the oblique communicating branches. Subsequently, the length of the CB and the distances of its proximal and distal points were measured in relation to the proximal and distal edges of the carpal flexor retinaculum.

For each of the morphometric evaluations, a digital caliper (Mitotuyo ®) was used and the findings were photographed with a Cannon T2I camera. After recording the macroscopic findings, the CBs was subjected to fixation with 10 % formaldehyde, stained with hematoxylin-eosin and evaluated under an optical microscope in order to either confirm or rule out the presence of a nervous microstructure.

The obtained findings were registered in Excel and the statistical analysis were performed in STATA 9.0. In the analysis of the data, the nominal variables were described

with their proportions, the continuous ones with their averages and standard deviation. The statistical tests of chi (X^2) square were carried out accepting an alpha error of up to 5 %.

RESULTS

A CB was observed in 82/106 (77.4 %) of the cadaveric specimens studied, of which, 28/53 (71.7 %) were bilateral, 15/53 (28.3 %) unilateral, this being a statistically significant difference ($p < 0.002$). In addition, 82 communications were found in the evaluated palmar regions, 45 right and 37 left, this not being significant statistical difference ($p = 0.71$).

Group I (Fig. 1) with a CB of oblique trajectory between the fourth and third common digital nerve was observed in 70/82 (85.4 %) palmar regions, showing a significant difference of this finding over the other groups ($p < 0.01$). Group II, with a transverse path between the fourth

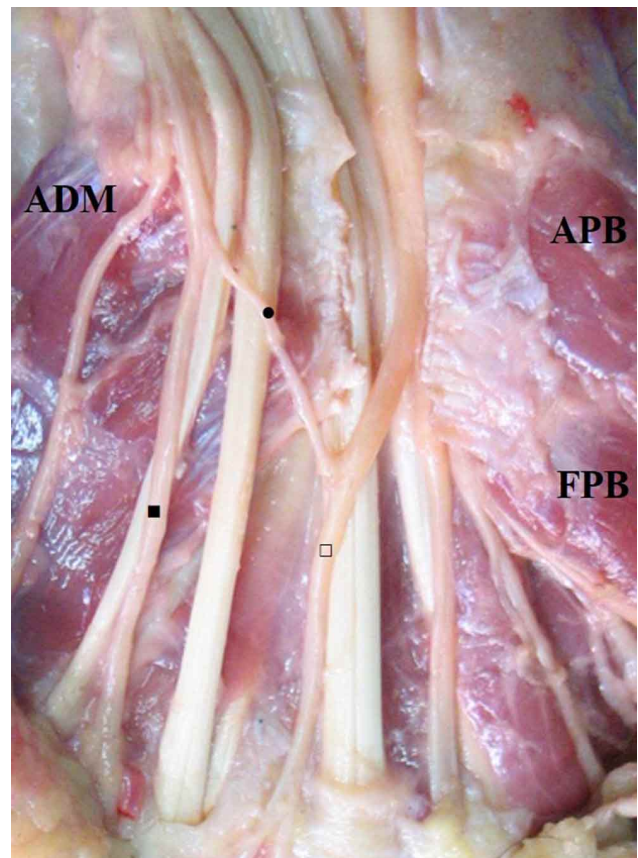


Fig. 1. Left palmar region, superficial plane.; FPB. Flexor Pollicis Brevis; APB. Abductor pollicis brevis muscle; ADM. Abductor digiti minimi muscle; (■) IV Common palmar digital nerve; (□) III Common palmar digital nerve; (●) Communicating branch with oblique trajectory ulnar-median.

and third common digital nerve (Fig. 2) was found in 7/82 (8.5 %) regions and on group III, with branches of plexiform shape (Fig. 3) was observed in 5 (6.1 %) cases.

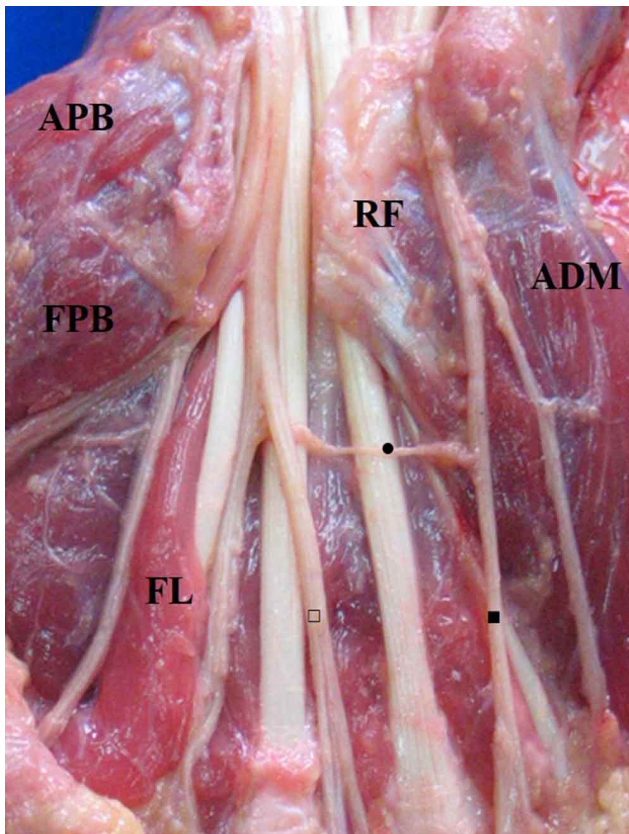


Fig. 2. Right palmar region, superficial plane. APB. Abductor pollicis brevis muscle; FPB. Flexor Pollicis Brevis; ADP. Adductor pollicis muscle; FR. Flexor retinaculum; FL. First lumbrical; ADM. Abductor digiti minimi muscle; (■) IV Common palmar digital nerve; (□) III Common palmar digital nerve; (●) Communicating branch with transverse trajectory.

The length of the CB was 20.2 ± 5.1 mm, corresponding to the right side 21.1 ± 5.7 mm, and to the contralateral side 19.4 ± 4.4 mm, without this difference being statistically significant ($P = 0.9$). The distances from the proximal edge of the flexor retinaculum to the proximal and distal points of the CB were 25 ± 6 mm and 37.4 ± 8.3 mm respectively. The length of the palm of the hand, measured from the bistyloid line of the wrist distal crease to the proximal digital fold of the third finger was 101 ± 8.8 mm; and when dividing the palm into five horizontal segments of 20.2 mm, the CB located in the second fifth proximal of the palmar region was observed in all cases. Likewise, in the histological evaluation of the samples obtained from the CB, it was observed that 100 % of the cases presented a microscopic structure of the peripheral nerve, identifying the epineural connective tissue and the fascicles surrounded by the perineurium (Fig. 4).

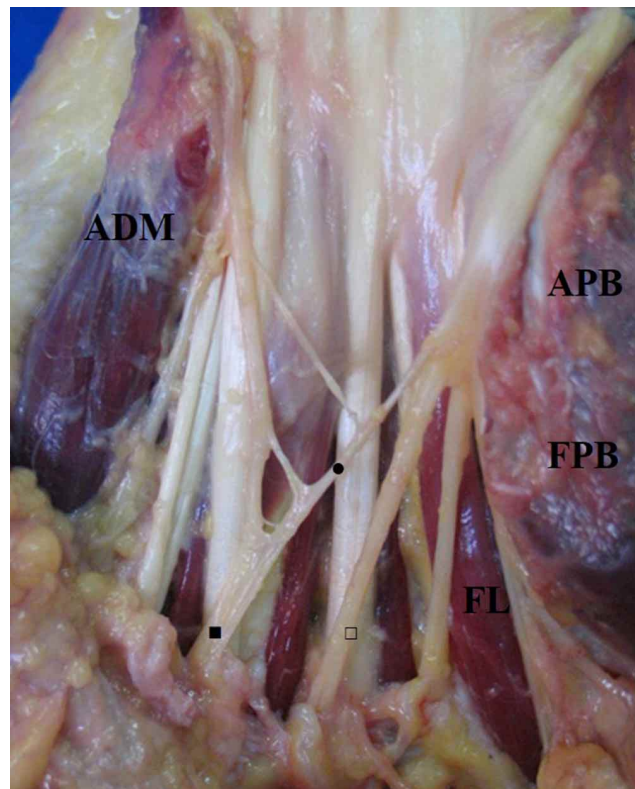


Fig. 3. Left palmar region, superficial plane.; APB. Abductor pollicis brevis muscle; FPB. Flexor Pollicis Brevis; ADM. Abductor digiti minimi muscle; FL. First lumbrical; (■) IV Common palmar digital nerve; (□) III Common palmar digital nerve; (●) Communicating branches.

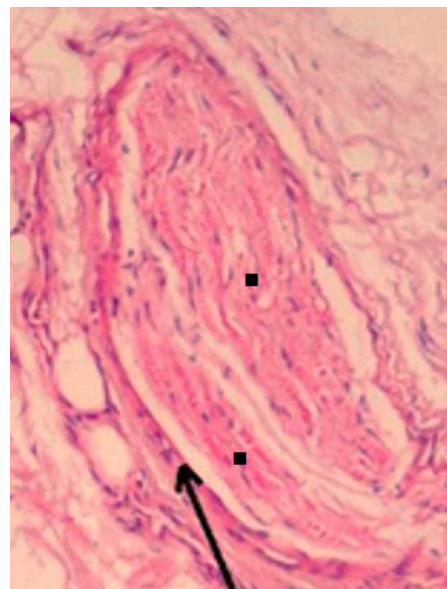


Fig. 4. Microphotography of an ulnar median communication in the superficial palmar region. the arrow indicates the epineurium. (■)Nerve fascicles of the communicating branch. 10X magnification, hematoxylin-eosin stain.

DISCUSSION

The frequency of CB is reported by the majority of authors in a range of 80-90 % (Meals & Shaner; Ferrari & Gilbert; Kimura *et al.*; Kolic *et al.*; Stancic *et al.*; Vieria *et al.*; Loukas *et al.*) even some studies (Don Griot *et al.*; Olave *et al.*) report incidents up to 96.4 %. The frequency of CB observed in our series (77.4 %) is in an intermediate range in relation to the majority of reports. Although, there are other reports that show a low range of 29.5 -74 % (Biafora & Gonzalez, 2007; Tagil *et al.*; Unver Dogan *et al.*, 2010; Yang *et al.*, 2016; Kara *et al.*, 2018). The wide variability in the presentation of this CB can be explained by differences in the size of the samples, methodologies used, and the various phenotypic biological expressions of the population groups evaluated.

In the dissection of the palm and identification of the CB, in some samples, it is possible to make the mistake of confusing a thin connective tissue band, biasing the results with figures higher than the real ones; therefore, histological confirmation is proposed in these cases, as was done in this study.

Regarding the classification of the CUMSP, group I, with CB of oblique trajectory between the fourth and third common digital nerve was the most frequently observed in our study (85.4 %) figure that is slightly higher than those indicated in previous works (Meals & Shaner; Ferrari & Gilbert; Kolic *et al.*; Don Griot *et al.*; Tagil *et al.*). Don Griot *et al.* (2000) report a frequency of 88 % for this anatomical expression. For group II, with CR of transverse trajectory, the frequency observed in our series was lower (8.5 %) than in most literature reports (Ferrari & Gilbert; Kolic *et al.*; Don Griot *et al.*; Tagil *et al.*), while group III, with branches of a plexiform form, our report of 6.1 % concurs with the studies that describe it with an incidence of 4-10 % (Ferrari & Gilbert; Don Griot *et al.*; Tagil *et al.*). In this study, we adopted a classification of the CUMSP (Ferrari & Gilbert) that, in addition to providing simple and accurate information, enriches the anatomical concept and constitutes a great contribution, allowing adequate approaches in the traditional and minimally invasive surgery of the palm of the hand.

The length of the CUMSP described by Don Griot *et al.* and Loukas *et al.* is similar to that found in our series (20.2 mm). Likewise, other morphometric aspects, such as the distances of the proximal and distal points of the CB to the upper edge of the flexor retinaculum (25 and 37.4 mm respectively) are in accordance with previous studies that indicate for these measurements, ranges of 24-30 mm and

40-43 mm respectively (Don Griot *et al.*; Olave *et al.*; Vieria *et al.*).

Tunnel carpal release is a common surgical procedure and better results have been shown when this is done by surgeons undergoing additional handtraining fellowship (Mathen *et al.*, 2018). Surgical treatment can be performed through open tunnel carpal release or endoscopic tunnel carpal release (Evers *et al.*, 2018). Neurological complications during tunnel carpal release can compromise the UN, NM and digital nerves (Verdecchia *et al.*, 2018). However, it is likely that CB can be compromised during tunnel carpal release procedures. Moreover, during clinical assessment, these CB lesions can be interpreted as digital nerve lesions given the similarity in sensitivity of the third interdigital volar space, thus be constituted as cause for legal medical litigation and clinical manifestations (persistent pain and numbness in addition to regional sympathetic dystrophy). All of these lesions can be similar to those described in this region (Benson *et al.*, 2006).

The presence of CUMSP, observed at the level of the second proximal fifth of the palmar region, makes it possible for this area to be vulnerable to complications associated with sharp cutting injuries or surgical procedures that can generate neuromas in these CB and also making the diagnosis difficult in hand clinical assessment of the hand. The anatomical characteristics in the patterns of CUMSP as well as the morphometric findings of the CB and its points of reference from the flexor retinaculum, allows delimitation of a safe surgical access area in the first fifth proximal of the palmar region, during the surgical approach of carpal tunnel syndrome.

ACKNOWLEDGMENTS

We would like to recognize the National Institute of Forensic Medicine, Northeastern Colombian region, for supplying the anatomical pieces used in this study.

QUINTERO, I. D.; BALLESTEROS, L. E.; FORERO, P. L. Comunicación superficial entre los nervios ulnar y mediano de la mano. Un estudio anatómico. *Int. J. Morphol.*, 39(6):1516-1520, 2021.

RESUMEN: El objetivo de este estudio fue caracterizar la comunicación entre los nervios ulnar y mediano en la región palmar superficial a partir de una muestra de población de raza mestiza predominante en América Latina. Se evaluaron las regiones palmares superficiales de 53 especímenes cadavéricos frescos, los cuales fueron sometidos procedimiento de necropsia en el Ins-

tituto de Medicina Legal. La disección se realizó por planos hasta visualizar la presencia del ramo comunicante (RC) entre los ramos digitales palmares del nervio ulnar (NU) y del nervio mediano (NM). Se realizó evaluación cualitativa y morfométrica del RC, observándose RC en 82/106 (77,4 %) de los especímenes cadavéricos estudiados, de los cuales 38/53 (71,7 %) eran bilaterales, 15/53 (28,3 %) unilaterales; siendo esta una diferencia estadísticamente significativa ($p < 0,002$). Se observó trayectoria oblicua del RC entre el cuarto y tercer nervio digital palmar común en 70 muestras (85,4 %), mientras que el RC con trayectoria transversal se encontró en 7 casos (8,5 %) y en forma plexiforme en 5 casos (6,1 %). La longitud del RC fue de $20,2 \pm 5,1$ mm y las distancias desde el margen superior del retináculo flexor hasta los puntos proximal y distal del RC fueron de 25 ± 6 mm y $37,4 \pm 8,3$ mm, respectivamente. Así, los hallazgos morfométricos del RC y sus puntos de referencia, desde el retináculo flexor, permiten delimitar una zona segura de acceso quirúrgico en el primer-quinto proximal de la región palmar, durante el abordaje quirúrgico del síndrome del túnel carpiano.

PALABRAS CLAVE: Liberación del túnel carpiano; Nervio mediano; Nervio ulnar.

REFERENCES

- Bas, H. & Kleinert, J. M. Anatomic variations in sensory innervation of the hand and digits. *J. Hand Surg. Am.*, 24(6):1171-84, 1999.
- Benson, L. S.; Bare, A. A.; Nagle, D. J.; Harder, V. S.; Williams, C. S. & Visotsky, J. L. Complications of endoscopic and open carpal tunnel release. *Arthroscopy*, 22(9):919-24, 924.e1-2, 2006.
- Biafora, S. J. & Gonzalez, M. H. Sensory communication of the median and ulnar nerves in the palm. *J. Surg. Orthop. Adv.*, 16(4):192-5, 2007.
- Don Griot, J. P.; Zuidam, J. M.; van Kooten, E. O.; Proisé, L. P. & Hage, J. J. Anatomic study of the ramus comunicans between the ulnar and median nerves. *J. Hand Surg. Am.*, 25(5):948-54, 2000.
- Evers, S.; Jansen, M. C.; Slijper, H.; de Haas, K. P.; Smit, X.; Porsius, J. T.; Hovius, S. E. R.; Amadio, P. C. & Selles, R. W. Hand surgeons performing more open carpal tunnel releases do not show better patient outcomes. *Plast. Reconstr. Surg.*, 141(6):1439-46, 2018.
- Ferrari, G. P. & Gilbert, A. The superficial anastomosis on the palm of the hand between the ulnar and median nerves. *J. Hand Surg. Br.*, 16(5):511-4, 1991.
- Kara, A. B.; Elvan, Ö.; Öztürk, N. C. & Öztürk, A. H. Communications of the median nerve in fetuses. *Folia Morphol. (Warsz)*, 77(3):441-6, 2018.
- Kimura, I.; Ayyar, D. R. & Lippmann, S. M. Electrophysiological verification of the ulnar to median nerve communications in the hand and forearm. *Tohoku J. Exp. Med.*, 141(3):269-74, 1983.
- Kolic, Z.; Micovic, V.; Zamolo, G.; Golubovic, V.; Uravic, M. & Stancic, M. F. The anatomy of the Berrettini branch: implications for endoscopic carpal tunnel release. *J. Neurosurg.*, 1997. DOI: <https://www.doi.org/10.3171/foc.1997.3.1.10>
- Loukas, M.; Louis Jr., R. G.; Stewart, L.; Hallner, B.; DeLuca, T.; Morgan, W.; Shah, R. & Mlejnek, J. The surgical anatomy of ulnar and median nerve communications in the palmar surface of the hand. *J. Neurosurg.*, 106(5):887-93, 2007.
- Mathen, S. J.; Nosrati, N. N. & Merrell, G. A. Decreased rate of complications in carpal tunnel release with hand fellowship training. *J. Hand Microsurg.*, 10(1):26-8, 2018.
- Meals, R. A. & Shaner, M. Variations in digital sensory patterns: a study of the ulnar nerve-median nerve palmar communicating branch. *J. Hand Surg. Am.*, 8(4):411-4, 1983.
- Olave, E.; del Sol, M.; Gabrielli, C.; Mandiola, E. & Rodrigues, C. F. Biometric study of the relationships between palmar neurovascular structures, the flexor retinaculum and the distal wrist crease. *J. Anat.*, 198(Pt. 6):737-41, 2001.
- Stancic, M. F.; Micovic, V. & Potocnjak, M. The anatomy of the Berrettini branch: implications for carpal tunnel release. *J. Neurosurg.*, 91(6):1027-30, 1999.
- Tagil, S. M.; Bozkurt, M. C.; Ozçakar, L.; Ersoy, M.; Tekdemir, I. & Elhan, A. Superficial palmar communications between the ulnar and median nerves in Turkish cadavers. *Clin. Anat.*, 20(7):795-8, 2007.
- Unver Dogan, N.; Uysal, I. I.; Karabulut, A. K.; Seker, M. & Ziyilan, T. Communications between the palmar digital branches of the median and ulnar nerves: A study in human fetuses and a review of the literature. *Clin. Anat.*, 23(2):234-41, 2010.
- Verdecchia, N.; Johnson, J.; Baratz, M. & Orebaugh, S. Neurologic complications in common wrist and hand surgical procedures. *Orthop. Rev. (Pavia)*, 10(1):7355, 2018.
- Vieria, L. A.; Caetano, M. B.; Yoshi, P. M.; Sabongi Netp. J. J. & Caetano, E. B. Estudo anatômico da anastomose entre os ramos sensitivos dos nervos ulnar e mediano na palma da mão. *Rev. Bras. Ortop.*, 37(8):336-40, 2002.
- Yang, H.; Gil, Y.; Kim, S.; Bang, J.; Choi, H. & Lee, H. Y. From the brachial plexus to the hand, multiple connections between the median and ulnar nerves may serve as bypass routes for nerve fibres. *J. Hand Surg. Eur. Vol.*, 41(6):648-56, 2016.

Corresponding author:
Ivan Dario Quintero. MD.
Division of Human Anatomy
Department of Basic Sciences
School of Medicine
Industrial University of Santander
Cra 32 N° 29-31
Bucaramanga
COLOMBIA

E-mail: ivanquinterop@gmail.com

Received: 20-07-2021

Accepted: 31-08-2021