

Morphology and Morphometry of the Hyoid Bone in a Black South African Population

Morfología y Morfometría del Hueso Hioides en una Población Sudafricana Negra

M. O. Shangase¹; S. Ishwarkumar² & P. Pillay¹

SHANGASE, M. O.; ISHWARKUMAR, S. & PILLAY, P. Morphology and morphometry of the hyoid bone in a black South African population. *Int. J. Morphol.*, 39(1):134-137, 2020.

SUMMARY: The hyoid is a unique, 'U' shaped bone, located on the anterior aspect of the neck, between the mandible and thyroid cartilage. This bone displays morphological and morphometric characteristics that can assist in determination of age, sex and race of an individual. Therefore, the present study aimed to investigate the morphology and morphometric parameters of the hyoid bone in a Black South African population of KwaZulu-Natal. The morphological and morphometric parameters of the 40 hyoid bones obtained from the Department of Clinical Anatomy, University of KwaZulu-Natal were classified in accordance with Deepak *et al.* (2013). In this study, 35 % of hyoid bones were 'U'-shaped and 65 % were 'V'-shaped in males, whereas in the female specimens, 70 % of hyoid bones were 'U'-shaped and 30 % 'V'-shaped. Furthermore, this study recorded a statistically significant relationship between the shape of the hyoid bone and sex. With regard to the morphometry, the width of the hyoid bone was greater in males than females however; the length of the hyoid bone was greater in females than males. In addition, this study concludes that these results may contribute to the existing knowledge on the morphology and morphometry of the hyoid bone and may assist forensic procedures.

KEY WORDS: Hyoid bone; South African Black population; Morphology and morphometry.

INTRODUCTION

The hyoid bone is typically a 'U'-shaped bone present in the anterior aspect of neck at the level of the fourth cervical vertebra, located between the mandible and thyroid cartilage (Moore *et al.*, 2014). Anatomically, it can be divided into 3 parts, viz. two greater cornu, a body and two lesser cornu (Leksan *et al.*, 2005). Literary reports states that the hyoid bone is a unique bone in the human skeleton, as it does not articulate directly with any other bone (Leksan *et al.*). It is attaches and supported by muscles and ligaments within the neck region (Leksan *et al.*).

Literature has documented variations that are present in the human skeletal system amongst different population groups around the world (Ubelaker & DeGaglia, 2017). The hyoid bone is one of the bones that has been classified to display sexually dimorphic features (Reesink *et al.*, 1999; Mukhopadhyay, 2010). Leksan *et al.* classified the morphology of the hyoid bone as being more asymmetrical in females as compared to males however; Deepak *et al.* reported that the hyoid bones of males displayed asymmetrical shapes as compared to the females. Balseven-

Odabasi *et al.* (2013) and Logar *et al.* (2016) concluded that the hyoid bone can be utilized to determine the sex of an individual in a Turkish and contemporary White population. Kindschuh *et al.* (2012) recorded ancestral differences in skeletal material of the African and the European population, whereby the hyoid bone of African descent was more elongated as compared to those of the European population, with the latter generally having larger hyoid bones.

Soltani *et al.* (2017) documented that the morphometry of the hyoid bone may be utilized to determine the sex of an individual. Furthermore, Okasi *et al.* (2018) stated that due to the sexual dimorphic features of the hyoid bone, it is viable option for sex determination, as this study further documented that the hyoid bones of males have a greater width, antero-posterior length and slope of cornua, as compared to the females.

Torimitsu *et al.* (2018) further encourages researchers to conduct more studies on the hyoid bone and its potential in determining age, sex, race and cause of death, within

¹ Department of Clinical Anatomy, School of Laboratory Medicine and Medical Sciences, College of Health Sciences, University of KwaZulu-Natal, Westville Campus, South Africa.

² Department of Human Anatomy and Physiology, Faculty of Health Sciences, University of Johannesburg, Doornfontein Campus, South Africa.

different population groups. Therefore, this study aimed to document the morphological and morphometric parameters of the hyoid bone within the Black South African.

MATERIAL AND METHOD

This study examined 40 hyoid bones (Male=20, Female=20) obtained from the Department of Clinical Anatomy, University of KwaZulu-Natal (Westville & Nelson R Mandela School of Medicine campuses). Ethical clearance was obtained (BE366/19). This study excluded any fragmented or damaged hyoid bones.

The morphological and morphometric methodology employed in this study was adapted from Deepak *et al.* The data was analysed using SPSS (Version: 15). The chi-square test and the T-test were utilized to determine if there were any statistical significance differences. A p-value <0.05 was deemed statistically significant.

Morphology of the hyoid bone methodology: The hyoid bone was classified in accordance with Deepak *et al.* as either 'U'-shaped (if the width is equal to or less than the length) or 'V'-shaped (if the width of the hyoid bone is greater than the length) (Fig. 1).

Morphometry of the hyoid bone methodology: The following morphometric parameters were measured using a digital calliper in accordance with Deepak *et al.*:

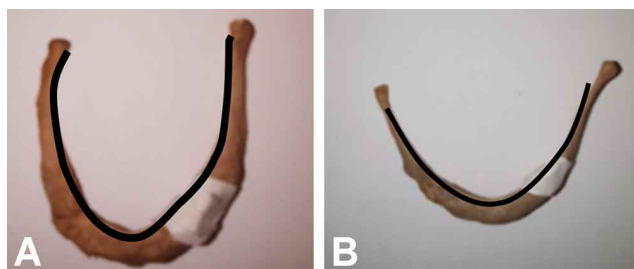


Fig. 1. (1) 'U'-shaped hyoid bone and (2) 'V'-shaped hyoid bone.

· Width of the hyoid bone (WD): Lateralmost distance between the greater cornua (a - b) (Fig. 2).

· Length of the hyoid bone (L): Middle distance from the anterior aspect of the body of the hyoid bone (c), to the point lying mid-way between the distances of the greater cornua (a - b) (Fig. 2).

Reliability and validity: Each morphometric parameter was measured three times by the first author and the mean value was calculated to ensure validity and reliability of this study.

RESULTS

Morphology of the hyoid bone: This study examined 40 hyoid bones, the 'U'-shaped hyoid bone more prevalent than the 'V'-shaped hyoid bone, with an incidences of 52.5 % and 47.5 %, respectively (Table I). The present study documented that 35 % and 65 % of the males had a 'U'-shaped and 'V'-shaped hyoid bones, respectively (Table I). However, 'U'-shaped hyoid bone was most prevalent among the females in this study, with an incidence of 70 %, while the remaining 30 % of female hyoid bones was 'V'-shaped (Table I). This study found a statistically significant relationship between the shape of the hyoid bone and sex, with a p-value of 0.027.

Morphometry of the hyoid bone: The mean width of the hyoid bone ranged between 29.56 mm - 52.84 mm in males and 29.83 mm - 44.88 mm in the female. The width of the hyoid bone was greater in males than females with a mean value of 37.07 mm and 36.75 mm, respectively (Table II).

However, the mean length of the hyoid bone was greater in females (37.45 mm) than males (35.70 mm) (Table II). This study found no statistical significant difference between the width and length of the hyoid bone and sex, with p-values of 0.826 and 0.932, respectively.




Fig. 2. (1) Width of the hyoid bone and (2) the Length of the hyoid bone.

Table I. Shape of the hyoid vs sex.

Shape	Male (n=20)	Female (n=20)	Total (n=40)	p-value
‘U’-shaped	7 (35 %)	14 (70 %)	21 (52.5 %)	0.027
‘V’-shaped	13 (65 %)	6 (30 %)	19 (47.5 %)	

Table II. Morphometric parameters of the hyoid vs sex.

Morphometric parameter	Male	Standard deviation	Female	Standard deviation
Mean width	37.07	4.7832	36.75	3.8864
Mean length	35.70	3.3170	37.45	3.0549

Table III. Literature comparison between the shape of the hyoid bones and sex.

Study	Year	Male		Female	
		‘U’- shape	‘V’- shape	‘U’ - shape	‘V’ – shape
Leksan <i>et al.</i>	2005	45.7 %	48.6 %	42.8 %	34.3 %
Deepak <i>et al.</i>	2013	44.0 %	56.0 %	55.0 %	45.0 %
Present study	2019	35.0 %	65.0 %	70.0 %	30.0 %

DISCUSSION

In the identification process of a deceased person determining the sex, age and race of the deceased is of vital importance (Okasi *et al.*). Okasi *et al.* further stated that due to the sexual dimorphic features of the hyoid bone, it is a feasible choice for sex determination of an individual.

Morphology of the hyoid bone: This study reported that the ‘V’-shape hyoid bone was most prevalent in males (65 %), while the ‘U’-shape is most prevalent in females (70 %) (Table III). These findings correlate with previous studies by Leksan *et al.* and Deepak *et al.* (Table III). The present study also recorded a statistically significant relationship between the shape of the hyoid bone and sex (p-value = 0.027).

Morphometry of the hyoid bone: In this study, the mean width of the hyoid bone in males were greater than female, which correlated with previous literature (Leksan *et al.*; Mukhopadhyay; Soltani *et al.*) (Table IV). In the present study, the mean length of the hyoid bone was great in females than males with a mean value of 37.46 mm and 35.70 mm, respectively (Table IV). This finding correlated with the study conducted by Kopuz & Ortug (Table IV). However, Leksan *et al.*, Kim *et al.* (2006), Mukhopadhyay, Balseven-Odabasi *et al.* and Soltani *et al.* reported that the length of hyoid bones in males was greater than their female counterparts (Table IV). Despite differences in the width and length of the hyoid bone between males and females, this study recorded no statistically significant relationship between these two parameters, with p-values of 0.826 and 0.932, respectively.

Table IV. Literature comparison of morphometric parameters of the hyoid bone.

Study	Year	Samplesize		Mean width ± STD Dev		Mean length ± STD Dev	
		Male	Female	Male	Female	Male	Female
Leksan <i>et al.</i>	2005	35	35	45.80 ± 6.7	40.50±6.4	41.40 ± 4.1	35.8 ± 3.9
Kim <i>et al.</i>	2006	52	35	45.8±12.8	35.4 ±16.1	39.7±3.2	33.9±6.6
Mukhopadhyay	2010	73	71	40.66±3.42	37.15±3.92	29.63±3.9	22.32 ± 2.1
Balseven-Odabasi <i>et al.</i>	2013	53	32	49.16±6.79	42.44±9.12	44.56±5.03	38.66±5.07
Kopuz & Ortug	2016	46	14	41.31±6.03	37.56±4.36	28.30±4.34	28.76±4.73
Soltani <i>et al.</i>	2017	173	176	38.71±1.92	30.26±2.18	38.97±1.43	30.33±2.01
Present study	2019	20	20	37.07±4.8	36.7±3.9	35.70± 3.3	37.46±3.05

CONCLUSION

Although the hyoid bone is small and fragile, when used in conjunction with other bones of the body, this bone may be utilized to assign age, sex and race (Kindschuh *et*

al.). This study recorded that the hyoid bone may be utilized to determine the sex of an individual, as a statistically significant relationship was documented between the

morphology of the hyoid bone and sex. Furthermore, the results of this study may contribute to the existing knowledge available on the morphology and morphometry of the hyoid bone and may assist forensic medicine.

Future Recommendation

The inclusion of age as a parameter is recommended for future studies, as this may add to the reliability of the study. Since, South Africa is a multiracial country, the documentation of the other ethnic groups is also warranted to ensure that population-specific data is available.

ACKNOWLEDGEMENTS

“Dr P Pillay is a University of KwaZulu-Natal (UKZN) Developing Research Innovation, Localisation and Leadership in South Africa (DRILL) fellow. DRILL, is a NIH D43 grant (D43TW010131) awarded to UKZN in 2015 to support a research training and induction programme for early career academics. The content is solely the responsibility of the authors and does not necessarily represent the official views of DRILL and the National Institutes of Health.”

SHANGASE, M. O.; ISHWARKUMAR, S. & PILLAY, P. Morfología y morfometría del hueso hioides en una Población Sudafricana Negra. *Int. J. Morphol.*, 39(1):134-137, 2020.

RESUMEN: El hioides es un hueso singular en forma de "U", ubicado en la región del cuello anterior, entre la mandíbula y el cartílago tiroideos, que presenta características morfológicas y morfométricas que pueden ayudar a determinar la edad, el sexo y la raza de un individuo. El objetivo de este estudio fue investigar la morfología y los parámetros morfométricos del hueso hioides en una población sudafricana negra de KwaZulu-Natal. Los parámetros morfológicos y morfométricos de los 40 huesos hioides obtenidos del Departamento de Anatomía Clínica de la Universidad de KwaZulu-Natal se clasificaron de acuerdo con Deepak *et al.* En este análisis, en los hombres el 35 % (7/20) de los huesos hioides tenían forma de 'U' y el 65 % (13/20) tenían forma de 'V', mientras que en las mujeres, el 70 % (14/20) de los huesos hioides tenían forma de 'U' y un 30 % (6/20) de 'V'. Además, se registró una relación estadísticamente significativa entre la forma del hueso hioides y el sexo. En cuanto a la morfometría, el ancho del hueso hioides fue mayor en los hombres que en las mujeres; la longitud del hueso hioides fue mayor en mujeres que en hombres. Además, el estudio concluye que estos resultados pueden contribuir al conocimiento existente sobre la morfología y morfometría del hueso hioides y pueden ayudar a los procedimientos forenses.

PALABRAS CLAVE: Hueso hioides; Población negra sudafricana; Morfología y morfometría.

REFERENCES

- Balseven-Odabasi, A.; Yalcinozan, E.; Keten, A.; Akçan, R.; Tumer, A. R.; Onan, A.; Canturk, N.; Odabasi, O. & Dinc, A. H. Age and sex estimation by metric measurements and fusion of hyoid bone in a Turkish population. *J. Forensic Leg. Med.*, 20(5):496-501, 2013.
- Deepak, D. H.; Jayaramaiah, K. & Sathyanarayana, H. S. Determination of sex by shape and size of hyoid bone. *J. Indian Acad. Forensic Med.*, 32(2):145-7, 2013.
- Kim, D. I.; Lee, U. Y.; Park, D. K.; Kim, Y. S.; Han, K. H.; Kim, K. H. & Han, S. H. Morphometrics of the hyoid bone for human sex determination from digital photographs. *J. Forensic Sci.*, 51(5):979-84, 2006.
- Kindschuh, S. C.; Dupras, T. L. & Cowgill, L. W. Determination of sex from the hyoid bone. *Am. J. Phys. Anthropol.*, 143(2):279-84, 2010.
- Kindschuh, S. C.; Dupras, T. L. & Cowgill, L. W. Exploring ancestral variation of the hyoid. *J. Forensic Sci.*, 57(1):41-6, 2012.
- Kopuz, C. & Ortug, G. Variable morphology of the hyoid bone in anatolian population: clinical implications - A cadaveric study. *Int. J. Morphol.*, 34(4):1396-403, 2016.
- Leksan, I.; Marcikic', M.; Nikolic', V.; Radic', R. & Selthofer, R. Morphological classification and sexual dimorphism of hyoid bone: new approach. *Coll. Antropol.*, 29(1):237-42, 2005.
- Logar, C. J.; Peckmann, T. R.; Meek, S. & Walls, S. G. Determination of sex from the hyoid bone in a contemporary White population. *J. Forensic Leg. Med.*, 39:34-41, 2016.
- Moore, K. L.; Dalley II, A. F. & Agur, A. M. R. *Clinically Oriented Anatomy*. 7th ed. Philadelphia : Wolters Kluwer Health/Lippincott Williams & Wilkins, 2014.
- Mukhopadhyay, P. Morphometric features and sexual dimorphism of adult hyoid bone: A population specific study with forensic implications. *J. Forensic Leg. Med.*, 17(6):321-4, 2010.
- Okasi, A.; Sadeghian, M. H.; Behnoush, B. & Rad, A. S. Sex identification by morphometric study of hyoid bone. *Int. J. Med. Toxicol. Forensic Med.*, 8(4):145-50, 2018.
- Reesink, E. M.; Van Immerseel, A. A. H.; Brand, R. & Brintjes, T. D. Sexual dimorphism of the hyoid bone? *Int. J. Osteoarchaeol.*, 9(5):357-60, 1999.
- Soltani, S.; Aghakhani, K. & Fallah, F. Sex prediction potential of hyoid metric measurements in Iranian adults. *Leg. Med.*, 25:6-10, 2017.
- Torimitsu, S.; Makino, Y.; Saitoh, H.; Ishii, N.; Yajima, D.; Inokuchi, G.; Motomura, A.; Chiba, F.; Yamaguchi, R.; Hoshioka, Y.; *et al.* Determination of sex on the basis of hyoid bone measurements in a Japanese population using multidetector computed tomography. *Int. J. Legal Med.*, 132(3):907-14, 2018.
- Ubelaker, D. H. & DeGaglia, C. M. Population variation in skeletal sexual dimorphism. *Forensic Sci. Int.*, 278:407.e1-407.e7, 2017.

Corresponding author:

Dr P. Pillay
Department of Clinical Anatomy
School of Laboratory Medicine and Medical Sciences
College of Health Sciences
University of KwaZulu-Natal
Private Bag X54001
Durban 4000
SOUTH AFRICA

Email: soobramoneya@ukzn.ac.za

Received: 27-08-2020

Accepted: 17-09-2020