

# Incidence of Metopism in Adult Thai Skulls

## Incidencia de Metopismo en Cráneos Tailandeses Adultos

Kimaporn Khamanarong<sup>\*</sup>; Panya Tuamsuk<sup>\*</sup>; Worawut Woraputtaporn<sup>\*</sup>; Malivalaya Namking<sup>\*</sup>;  
Tarinee Sawatpanich<sup>\*</sup>; Yanyong Toomsan<sup>\*</sup> & Sitthichai Iamsaard<sup>\*</sup>

---

**KHAMANARONG, K.; TUAMSUK, P.; WORAPUTTAPORN, W.; NAMKING, M.; SAWATPANICH, T.; TOOMSAN, Y. & IAMSAARD, S.** Incidence of metopism in adult Thai skulls. *Int. J. Morphol.*, 33(1):51-54, 2015.

**SUMMARY:** The persistent metopic suture on adult skull (also known as metopism) can confuse the clinicians during diagnosis of the frontal bone fractures in emergency conditions. The incidences of metopism have been documented in many populations except in Thais. Therefore, this study was aimed to determine the incidence of metopism in adult Thai skulls. The identified 706 Thai dried skulls (481 males and 225 females) were carried out for metopic suture observations. The results showed that 53 skulls (7.51%) were present of the metopic sutures. The metopism observed could be classified into major two types (complete metopic suture (20 skulls [2.83%]) and incomplete metopic suture (33 skulls [4.67%]). For the incomplete metopic suture could be further classified into two subtypes, bregma-incomplete metopic suture and nasion-incomplete metopic suture. This incidence maybe a basic information for Thai radiologists to concern about metopic suture in emergency diagnosis of frontal bone fractures.

**KEY WORDS:** Metopism; Metopic suture; Frontal bone.

---

## INTRODUCTION

The metopism is a rare variant suture present on the adult frontal bone because it fails to fuse in early childhood. It is also called the metopic suture or median frontal suture that separates the two halves of the frontal bone in the vertical plane. Although this suture can be found in every newborn skull, the actual disappearance of metopic suture is still recently controversy. Previous investigations have suggested that metopic suture could vary disappear at the end of first year, or in the early second year (Keith, 1948), at the end of the fourth year (Piersol, 1916), by the fifth or sixth year (Romanes, 1972; Torgerson, 1951), by the seventh year (Hamiton, 1976), or by the eight year (Warwick & Williams, 1980). However, in general textbooks of anatomy, metopic suture is defined to usually disappear from infancy to in early childhood.

Clinically, the persistent metopic suture can confuse the radiologists and neurosurgeons during reading the films of X-ray, CT, or MRI in wrong diagnosis in urgent situations. Therefore the knowledge of the metopism incidence in different races is important and should be considered before diagnosis of frontal bone fractures. Previously, the incidence of metopic suture has been reported in many populations such as Scottish (Bryce, 1915), Australian (Bryce), Mongolian (Bryce), European (Bryce), Nigerian (Ajmani *et al.*, 1983), Nepalese (Bilodi *et al.*, 2004) Lebanese (Baaten *et al.*, 2003), Brazilian (Castilho *et al.*, 2006), Indian

(Murlimanju *et al.*, 2011), Turkish (Bilgin *et al.*, 2013), and West Anatolian (Aksu *et al.*, 2014). Recently, there is no report of this incidence from Thai population. Therefore we aimed to determine the incidence of metopic suture in Thai adult skulls.

## MATERIAL AND METHOD

Seven hundred and six dried skulls (481 males and 225 females), ranging from 29–92 years, were carried out for metopic sutural observations. All skulls were identified and recorded systematically from the Osteological Collection Unit, Department of Anatomy, Faculty of Medicine, Khon Kaen University, Thailand. The analysis of the metopic suture was made by investigation on the skulls at frontal bone. The metopic suture was considered as complete metopic suture when it is present of extra continuous suture extending between the nasion and the bregma (Figs. 1A, 2A and 2B). In addition, the incomplete metopic suture was considered when finding of partial suture extending either from the bregma or from the nasion (Figs. 1B, 1C, 2C and 2D). Note that skulls with visible deformities were excluded from this study. The incidences of all metopic sutures were represented as number of skulls and percentage.

<sup>\*</sup> Department of Anatomy, Faculty of Medicine, Khon Kaen University, Khon Kaen, Thailand.

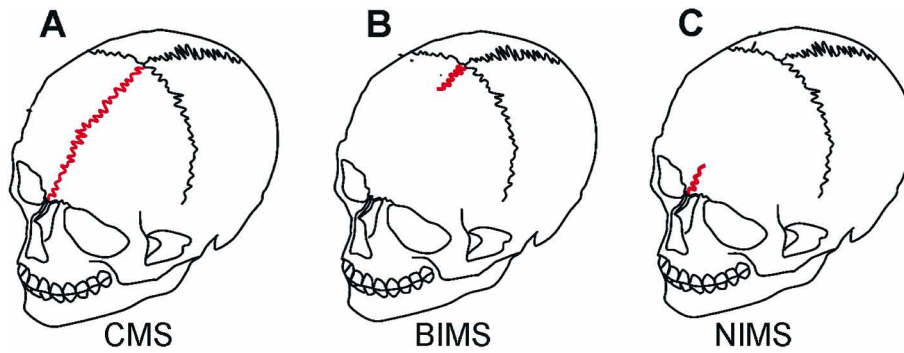


Fig. 1 Schematic drawing of three different metopic sutures on skulls observed in this study. A. Complete metopic suture (CMS), B. Bregma-incomplete metopic suture (BIMS), and C. Nasion-incomplete metopic suture (NIMS).

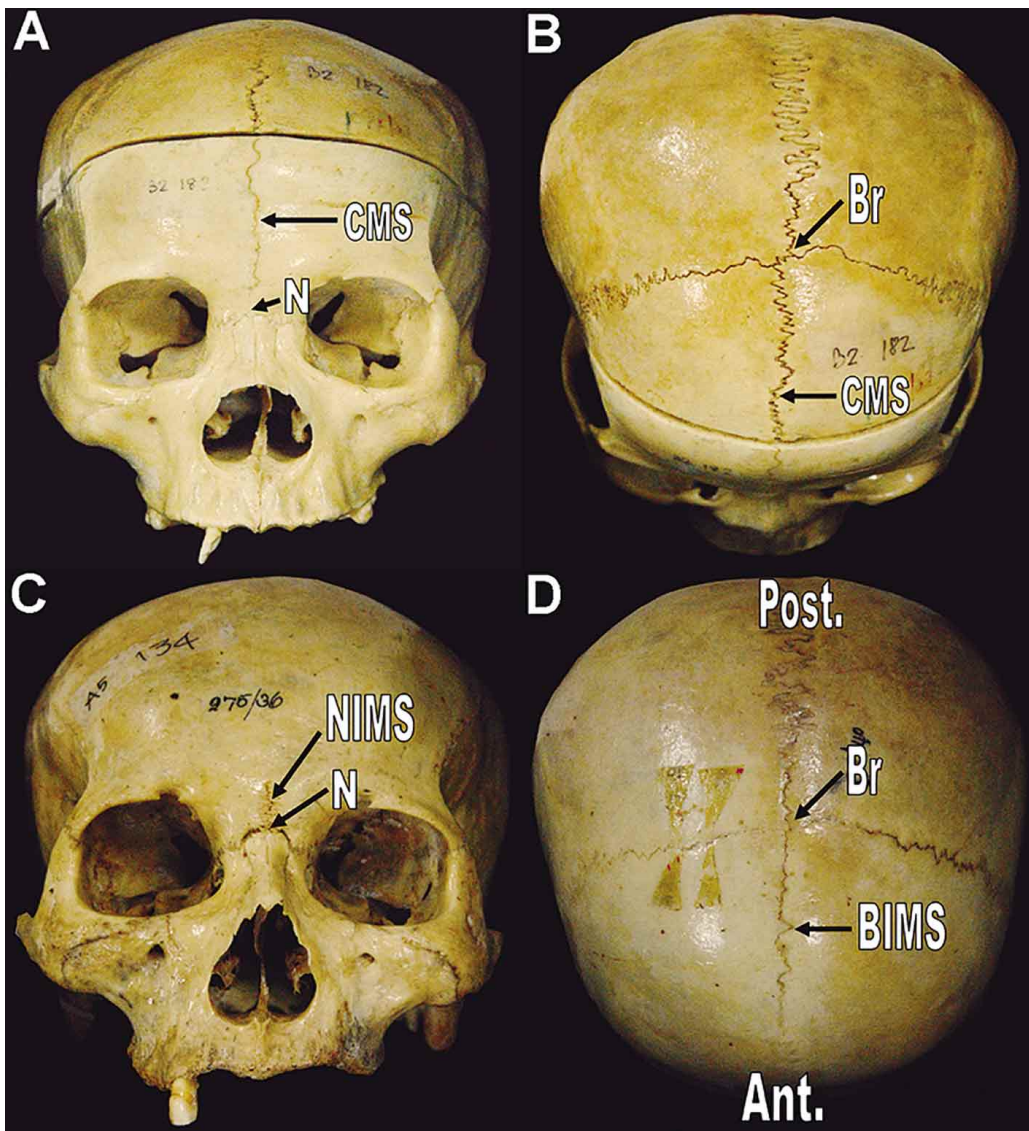


Fig. 2 Showing representative dried skulls with variant metopic sutures. A. anterior view and B. superior view, complete metopic suture (CMS), C. anterior view, nasion- incomplete metopic suture (NIMS), D. superior view, bregma-incomplete metopic suture (BIMS). Br = bregma, N= nasion, Ant.= anterior, Post.= posterior.

## RESULTS

On 706 dried skulls, the results showed that 53 skulls (7.51%) were present of the metopic sutures found 29 (4.11%) skulls in men and 24 (3.40%) skulls in woman (Table I). The metopic sutures observed in this study could be classified into two types (Figs. 1 and 2). The first type was the complete metopic suture (CMS) and the second type was incomplete metopic suture (ICMS), which could be further classified into two subtypes, bregma-incomplete metopic suture (BIMS) and nasion- incomplete metopic suture (NIMS). The CMS type, a suture running between nasion and bregma (Figs. 1A, 2A and 2B), was found in 20 skulls (2.83%); 11 (1.56%) seen in men and 9 (1.28%) in women. For the ICMS, the incidence of BIMS (Figs. 1B and 2D) and NIMS (Figs. 1C and 2C) were 33 skulls (4.67%) found 18 skulls in men (2.55%) and skulls 15 in women (2.12%) as shown in Table I.

Table I. Incidence of the metopic sutures observed on 706 dried skulls of unidentified adult Thais.

Metopic sutural types	Males	Females	Total
Complete metopic suture	11 (1.56%)	9 (1.28%)	20 (2.83%)
Incomplete metopic suture	18 (2.55%)	15 (2.12%)	33 (4.67%)
Total	29 (4.11%)	24 (3.40%)	53 (7.51%)

## DISCUSSION

This is the first report about the incidence of metopic suture determined in 706 dried skulls of identified Thai adults. In the same veins of a previous study (Skrzat *et al.*, 2004), this present study also classified the metopic suture into two major patterns or shapes (complete and incomplete) (Table I). In addition, the incomplete metopic suture can be subdivided into two types: bregma-incomplete metopic suture (BIMS) and nasion-incomplete metopic suture (NIMS) as shown in Figures 1 and 2. Moreover, there was a report showing five shapes (complete, incomplete, linear, V, and double) of metopic suture in Indian population (Murlimanju *et al.*). As compared to total incidence of metopic suture among racial variations, the incidence in the present Thai study (7.51%) is very close to that of Brazilian population (7.4%) (Castilho *et al.*), and higher than that of Australian (1%) (Bryce), Mongolian (5.1%) (Bryce), Nigerian (3.4%) (Ajmani *et al.*), Nepalese (3.93%) (Bilodi *et al.*), Lebanese (0.82%) (Baaten *et al.*), Indian (1.2%) (Murlimanju *et al.*). With respect to sex, the metopic suture in both types is found to be higher in males than in females (Table I) witch corresponds to that of Indian and Lebanese populations (Murlimanju *et al.*; Baaten *et al.*). Similar to the other populations, the incidence of incomplete metopic suture of Thais was higher than that of the complete metopic suture (Table I). Interestingly, the fusion or disappearance of the metopic suture in Thai population

is still unknown and needs further investigations. The information or awareness about the incidence of persistent metopic suture is very important for clinicians in emergency diagnosis of some adult head injury cases to prevent misinterpreted as vertical frontal fracture in x-rays, CT, or MRI film. In conclusion, the present study has provided the first incidence of metopic suture in the Thai adult population.

## ACKNOWLEDGEMENTS

We would like to thank the Osteological Collection Unit, Department of Anatomy, Faculty of Medicine, Khon Kaen University, Thailand for providing the identified human skulls.

---

**KHAMANARONG, K.; TUAMSUK, P.; WORAPUTTAPORN, W.; NAMKING, M.; SAWATPANICH, T.; TOOMSAN, Y. & IAMSAARD, S.** Incidencia de metopismo en cráneos tailandeses adultos. *Int. J. Morphol.*, 33(1):51-54, 2015.

**RESUMEN:** La persistencia de la sutura metópica en el cráneo adulto (también conocido como metopismo) puede provocar confusión en los médicos durante el diagnóstico de las fracturas de los huesos frontales en situaciones de emergencia. La incidencia de metopismo se ha documentado en muchas poblaciones, excepto en individuos tailandeses. Por lo tanto, este estudio tuvo como objetivo determinar la incidencia de metopismo en cráneos tailandeses adultos. Se identificaron 706 cráneos secos (481 hombres y 225 mujeres) y se llevó a cabo la observación de la sutura metópica. Los resultados mostraron que en 53 cráneos (7,51%) estaba presente la sutura metópica. Según nuestras observaciones, el metopismo podría ser clasificado en dos tipos principales: sutura metópica completa (20 cráneos [2,83%]) y sutura metópica incompleta (33 cráneos [4,67%]). A su vez, la sutura metópica incompleta podría ser clasificada en dos subtipos: sutura metópica incompleta "bregma" y sutura metópica incompleta "nasion". Consideramos que la incidencia de metopismo registrado en este trabajo configura una información de relevancia para los radiólogos tailandeses en relación a la sutura metópica y el correcto diagnóstico en la emergencia de fracturas óseas frontales.

**PALABRAS CLAVE:** Metopismo; Sutura metópica; Hueso frontal.

## REFERENCES

- Ajmani, M. L.; Mittal, R. K. & Jain, S. P. Incidence of the metopic suture in adult Nigerian skulls. *J. Anat.*, 137(Pt. 1):177-83, 1983.
- Aksu, F.; Cirpan, S.; Mas, N. G.; Karabekir, S. & Magden A. O. Anatomic features of metopic suture in adult dry skulls. *J. Craniofac. Surg.*, 25(3):1044-6, 2014.
- Baaten, P. J.; Haddad, M.; Abi-Nader, K.; Abi-Ghosn, A.; AI-Kutoubi, A. & Jurjus, A. R. Incidence of metopism in the Lebanese population. *Clin. Anat.*, 16(2):148-51, 2003.
- Bilgin, S.; Kantarcı, U. H.; Duymus, M.; Yildirim, C. H.; Ercakmak, B.; Orman, G.; Gunenc Beser, C.; Kaya, M.; Gok, M. & Akbasak, A. Association between frontal sinus development and persistent metopic suture. *Folia Morphol. (Warsz.)*, 72(4):306-10, 2013.
- Bilodi, A. K.; Agrawal, B. K.; Mane, S. & Kumar, A. A study of metopic sutures in human skulls. *Kathmandu Univ. Med. J. (K. U. M. J.)*, 2(2):96-9, 2004.
- Bryce, T. H. *Osteology and arthrology*. In: Quain, J. Quain's Elements of Anatomy. 11<sup>th</sup> ed. London, Longman Green, 1915. V. 4. pp.177.
- Castilho, M. A. S.; Oda, J. Y. & Sant'Ana, D. M. G. Metopism in adult skulls from Southern Brazil. *Int. J. Morphol.*, 24(1):61-6, 2006.
- Hamiton, W. J. *Textbook of Human Anatomy*. 2<sup>nd</sup> ed. London, Macmillan & Co., 1976. pp.60.
- Keith, A. *Human Embryology and Morphology*. 6<sup>th</sup> ed, London, Edward Arnold, 1948.
- Murlimanju, B. V.; Prabhu, L. V.; Pai, M. M.; Goveas, A. A.; Dhananjaya, K. V. & Somesh, M. S. Median frontal sutures - incidence, morphology and their surgical, radiological importance. *Turk. Neurosurg.*, 21(4):489-93, 2011.
- Piersol, G. A. *Human Anatomy*. 5<sup>th</sup> ed. Philadelphia, Lippincott, 1916.
- Romanes, G. J. *Cunningham's Textbook of Anatomy*. 11<sup>th</sup> ed. London, Oxford University Press, 1972. pp.133.
- Skrzat, J.; Walocha, J. & Zawilinski, J. A note on the morphology of the metopic suture in the human skull. *Folia Morphol. (Warsz.)*, 63(4):481-4, 2004.
- Torgerson, J. Developmental, genetic evolutionary meaning of metopic suture. *Am. J. Phys. Anthropol.*, 9:193-210, 1951.
- Warwick, R. & Williams, P. L. *Gray's Anatomy*. 36<sup>th</sup> ed. London, Longmans, 1980. pp.334.

Correspondence to:  
Sitthichai Iamsaard  
Department of Anatomy  
Faculty of Medicine  
University Muang Khon Kaen  
Khon Kaen, 40002  
THAILAND

Email: [sittia@kku.ac.th](mailto:sittia@kku.ac.th)

Received: 14-07-2014  
Accepted: 06-12-2014