

Third Head of Biceps Brachii Muscle, Associated with Musculocutaneous and Median Nerve Bilateral Communication and with a Communicating Branch Between Median Nerve Roots

Tercera Cabeza del Músculo Bíceps Braquial Asociada a la Comunicación Bilateral de los Nervios Musculocutáneo y Mediano y a un Ramo Comunicante entre las Raíces del Nervio Mediano

Aladino Cerda^{*,**}

CERDA, A. Third head of biceps brachii muscle, associated with musculocutaneous and median nerve bilateral communication and with a communicating branch between median nerve roots. *Int. J. Morphol.*, 32(2):510-514, 2014.

SUMMARY: Both biceps brachii muscle anatomical variations and the presence of communicating branches between the musculocutaneous nerve and the median nerve are common, and have clinical significance due to their connections and vulnerability. A case found during a routine dissection of the upper limb of a male cadaver is described, in which unilateral presence of a third head of the biceps brachii muscle coexists associated to a bilateral communication of the musculocutaneous nerve with the median nerve, and a unilateral communicating branch between the roots of median nerve. The morphological features and the prevalence of the case are presented, besides the discussion of its clinical significance.

KEY WORDS: Biceps brachii; Musculocutaneous nerve; Median nerve; Brachial plexus; Anatomical variations.

INTRODUCTION

The biceps brachii muscle has two heads, a short one originated in the apex of the coracoids process, and a long head originated in the supraglenoid tubercle of scapula (García-Porrero & Hurlé, 2005). However, several articles in the literature report supernumerary heads of the biceps brachii muscle (Rodríguez-Niedenführ *et al.*, 2003; Abu-Hijleh, 2005; Vollala *et al.*, 2008; Ilayperuma *et al.*, 2011; Ongeti *et al.*, 2012). Some authors have described the coexistence of communicating branches between musculocutaneous nerve and median nerve associated to presence of an accessory humeral head of the biceps brachii muscle (Nayak *et al.*, 2006; Pacholczak & Klimek-Piotrowska, 2011; Ongeti *et al.*).

The musculocutaneous nerve, which is a branch of the lateral cord of the brachial plexus, passes through the coracobrachialis muscle to innervate it. Then it proceeds between biceps brachii and brachial muscles giving branches to innervate them, and continues as the lateral cutaneous nerve of the forearm without any communication with the median nerve, or other nerve (Sontakke *et al.*, 2010). The median nerve is constituted by a lateral and medial root; both originate from lateral and medial cords of the brachial plexus, respectively. Afterward, it traverses the lower portion of the axillary fossa, descends through the arm and forearm, goes deep the flexor

retinaculum and finally reaches the hand palm, where it divides in its terminal branches.

The objective of this study was to describe the topographic anatomy of these anatomical variations and discuss its clinical implications.

CASE REPORT

During a routine dissection of the upper limbs of a male cadaver, in the Morphology Laboratory of the Universidad de Talca, multiples anatomical variations were observed. Axillary and brachial regions were carefully dissected, and identified the constituent nerve roots of brachial plexus, besides the route and distribution of its terminal branches.

In the left upper limb (Fig. 1) a biceps brachii muscle third humeral head was observed. That third head originated at the humeral medial face, at level of third middle of arm, between coracobrachialis muscle insertion and brachialis muscle origin. It was 14.9 cm length and was joined to the

* Unidad de Anatomía, Departamento de Ciencias Básicas Biomédicas, Facultad de Ciencias de la Salud, Universidad de Talca, Talca, Chile.

** Programa de Magíster en Ciencias, mención Morfología, Facultad de Ciencias de la Salud, Universidad de la Frontera, Temuco, Chile.

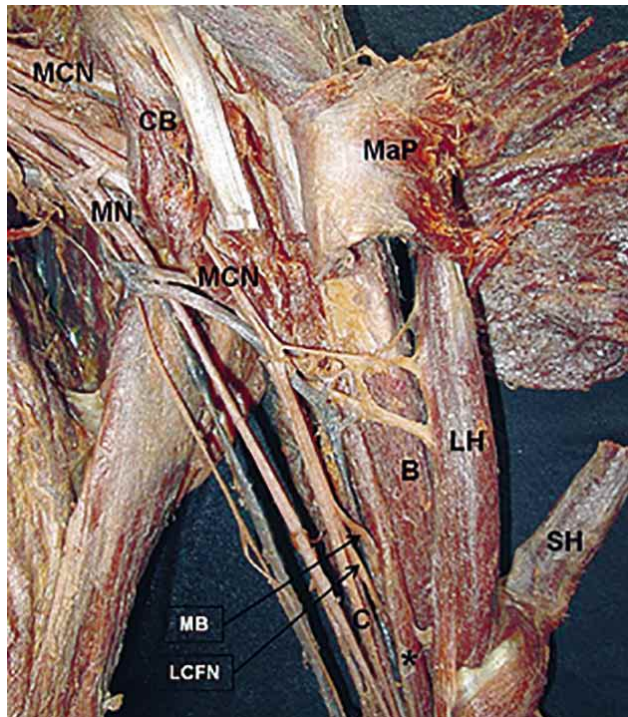


Fig. 1. Anterior view of left arm. MaP: major pectoral muscle; CB: coracobrachialis muscle; MCN: musculocutaneous nerve; LH: long head of the biceps brachii muscle; SH: short head of the biceps brachii muscle; B: brachialis muscle; *: third head of the biceps brachii muscle; MB: muscular branch; LCFN: lateral cutaneous forearm nerve; C: communicating branch; MN: median nerve.

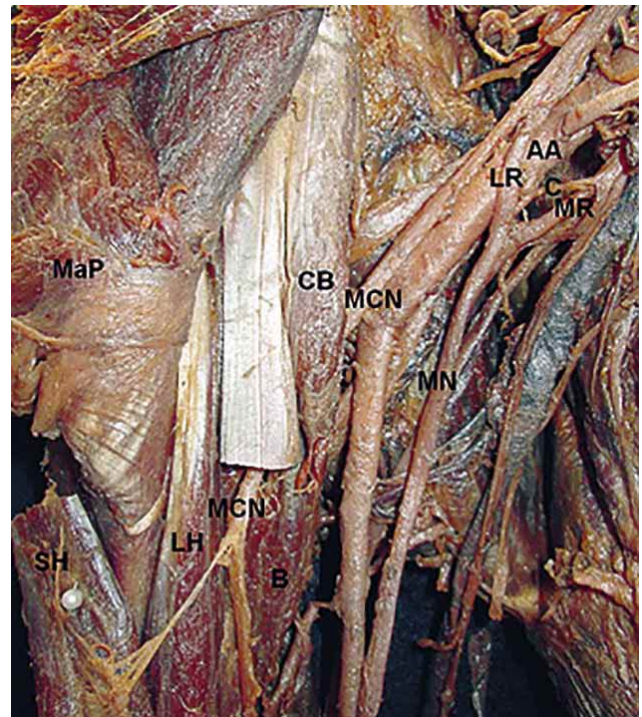
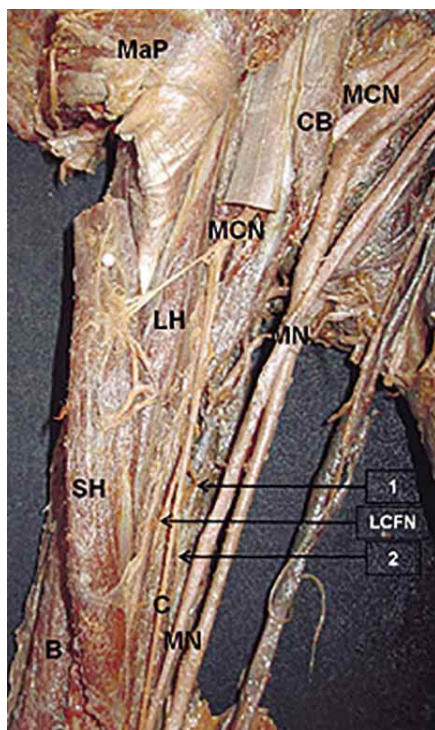


Fig. 3. Anterior view of right axilla. MaP: major pectoral muscle; CB: coracobrachialis muscle; MCN: musculocutaneous nerve; LH: long head of the biceps brachii muscle; SH: short head of the biceps brachii muscle; B: brachialis muscle; LR: lateral root of the median nerve; MR: medial root of the median nerve; C: communicating branch; AA: axillary artery; MN: median nerve.



biceps brachii tendon at level of third lower of arm. In this limb, we also observed the presence of a communicating branch between musculocutaneous and median nerve. In this case the musculocutaneous nerve penetrated the coracobrachialis muscle and gave three terminal branches at level of third lower of arm; a muscular branch to innervate the brachial muscle, the lateral cutaneous forearm nerve, and a communicating branch that originated 19.1 cm away from the apex of the coracoid process with a 7.7 cm length and a 1.6 mm thickness, and finally it connected to median nerve to 25.9 cm away from the coracoid process.

In the right upper limb (Fig. 2) the musculocutaneous nerve penetrated the coracobrachialis muscle and gave four terminal branches at level of third lower of arm; two muscular branches for the brachial muscle, the lateral cutaneous forearm nerve and a communicating branch. The last one originated 18.4 cm away from the apex of the coracoid process; next it descends to medial with a 9.4 cm length and 1.2 mm thickness, and finally connects to median nerve 28.7 cm away from the apex of coracoid process. The presence of a little communicating branch that originated from the medial root of the median nerve was also observed, descended obliquely to lateral, crossing anterior of axillary artery and finally connecting to the lateral root of median nerve, at 0.4 cm away from its origin; presented a 2.1 cm length and 1 mm thickness (Fig. 3).

Fig. 2. Anterior view of right arm. MaP: major pectoral muscle; CB: coracobrachialis muscle; MCN: musculocutaneous nerve; LH: long head of the biceps brachii muscle; SH: short head of the biceps brachii muscle; B: brachialis muscle; 1 and 2: muscular branches; C: communicating branch; LCFN: lateral cutaneous forearm nerve; MN: median nerve.

DISCUSSION

The presence of the supernumerary heads of the biceps brachii muscle has been associated with variations of the musculocutaneous nerve; likewise, it has been associated with the presence of communicating branches, between the median nerve and musculocutaneous nerve (Rodríguez-Niedenführ *et al.*; Abu-Hijleh; Pacholczak & Klimek-Piotrowska). The embryological development of the upper limbs may help in explaining this anatomical variation. The mesenchyme, which forms the upper limb muscles, is penetrated by the ventral primary branches of the appropriate spinal nerves, located opposite to the bud. Contact between nerves and muscle cells, is necessary to provide mesenchymal condensation to form muscles. Nerves supplying the limbs are joined by loops connection of nerve fibers to form plexuses. The median nerve is formed by a combination of ventral segmental branches and the musculocutaneous nerve arises from it (Pacholczak & Klimek-Piotrowska). The development of the biceps brachii third humeral head may have influenced the course or the ramification patterning of variant musculocutaneous nerve, or vice versa, and could explain the coexistence of such neuromuscular anomaly (Abu-Hijleh).

The presence of a third humeral head is the most common anatomical variation of biceps brachii muscle (Rodríguez-Niedenführ *et al.*) and has been frequently reported (Rodríguez-Niedenführ *et al.*; Abu-Hijleh; Vollala *et al.*; Ilayperuma *et al.*; Ongeti *et al.*). The presence of four or even seven biceps brachii muscle heads has also been reported (Catli *et al.*, 2012). The available combinations of these variations have resulted in a large number of reports and studies, with different classification systems, making comparison difficult (Rodríguez-Niedenführ *et al.*).

Rodríguez-Niedenführ *et al.*, classifies the supernumerary heads of biceps brachii muscle according its location, as a superior humeral head, inferomedial and inferolateral. The superior humeral head, presents a proximal attachment in the surface of the humerus, between the lesser tubercle, the brachial and coracobrachial muscles. Then it continues inferiorly, deep to the short head of biceps brachii muscle and superficial to the anterior humeral circumflex artery, and merges with muscle fibers of the short head of biceps brachii muscle in its join with the long head. The inferomedial head has a proximal attachment in the anteromedial surface of humerus, continues with the insertion of coracobrachialis muscle and closely related to the medial intermuscular septum and brachial muscle; then continues inferiorly, deep to the biceps brachii muscle and superficial to the brachial muscle, inserting in the medial border of the

biceps brachii tendon. The inferolateral head originates in the lateral intermuscular septum, between the insertion of the deltoid and the origin of the brachioradialis muscle, and joins to the long head of the biceps brachii muscle at the level of lower third of arm. According to this classification, the third head of biceps brachii muscle found in this case corresponds to an inferomedial humeral head. According Rodríguez-Niedenführ *et al.* this is the most common variation (9%).

Anatomical variations and anomalies of the upper extremity muscles are significant, because doctors can find such abnormalities during image forming with computed tomography and magnetic resonance imaging (Catli *et al.*). Magnetic resonance imaging and computed tomography play an important role in distinguishing between normal anatomical structures and pathological lesions of the upper extremity, as well as serving as a guide for planning surgical resection. Therefore, the presence of an accessory head can lead to confusion (Kervancioglu & Orhan, 2011). In most cases, the accessory heads are asymptomatic and represent incidental findings encountered during surgery or images (Kervancioglu & Orhan). From a clinical standpoint, muscle anomalies are difficult to differentiate from soft tissue tumors (Nayak *et al.*, 2008). The existence of accessory muscles in the arm and forearm may confuse surgeons during procedures, cause compression of the neurovascular structures, or lead to the variation of the normal mechanical action (Lee *et al.*, 2011). If the variation is unilateral, this can be the cause of the mismatch between the two arms, which can be easily confused with pathological conditions such as tumors (Kervancioglu & Orhan).

An accessory head of biceps brachii could cause an additional force or an unusual displacement of the fragments of the humerus after fracture (Mas *et al.*, 2006). According Balasubramanian (2010), this third head of the biceps brachii would allow flexion of the elbow joint, irrespective of the position of the shoulder joint. Ongeti *et al.* add that these unusual muscles also enhance supination.

The presence of communicating branches between the musculocutaneous nerve and median nerve are common, and has been reported by several authors (Venieratos & Anagnostopoulou, 1998; Choi *et al.*, 2012; Loukas & Aqueelah, 2005; Anyanwu *et al.*, 2009; Cerda & Suazo, 2012). The most frequent variation consists in the presence of a communicating branch, originated from the musculocutaneous nerve and joins distally to the median nerve, at level of lower third of arm (Venieratos & Anagnostopoulou). Such variations are predominantly unilateral (Saed & Rufai, 2003). According Choi *et al.* the bilateral variations are very rare.

The communication between the musculocutaneous nerve and median nerve has been classified by many authors, based on different criteria (Cerde & Suazo). Venieratos and Anagnostopoulou classified communications between the median nerve and musculocutaneous nerve into three types, according its relationship with coracobrachialis muscle. In the types I and II communications are proximal and distal at the entry point of the musculocutaneous nerve in the coracobrachialis muscle, respectively. In the type III the musculocutaneous nerve, as well as the communicating branch, do not penetrate coracobrachialis muscle. According to this classification the communicating branches between the musculocutaneous nerve and median nerve found in this case correspond to type II, in both upper limbs. . In six subjects of the study by Venieratos & Anagnostopoulou these communications were bilateral. Within the six subjects, one presented a pattern type II bilateral (1.3%; 1 of 79 cadavers), the same as found in this case.

Choi *et al.* classified the communicating branch between the musculocutaneous nerve and median nerve in three patterns, based on the communicating branch numbers or the fusion of both nerves. In the pattern I the musculocutaneous nerve and median nerve merge forming a trunk. In pattern II and III two and three communicating branches between musculocutaneous nerve and median nerve were present, respectively. According to this description, the findings in this case may be classified as a pattern II in both upper limbs. Loukas & Aqueelah classified the communications between the musculocutaneous nerve and median nerve in four models, according to its relationship with coracobrachialis muscle. In type I and II the communications are proximal and distal to the entry point of the musculocutaneous nerve in the coracobrachial muscle,

respectively; meanwhile, in the type III the musculocutaneous nerve does not penetrate the coracobrachialis muscle, and in type IV both types I and II coexist. According to this classification, the findings in this report correspond to a pattern type II, in both upper limbs.

Clinically, these variations may be related to entrapment syndrome. If the entrapment of the musculocutaneous nerve coexists with a communicating branch between the musculocutaneous and median nerve may lead symptoms of median nerve neuropathy (Goyal *et al.*, 2005). This knowledge may result useful to doctors to avoid an unnecessary carpal tunnel release (Venieratos & Anagnostopoulou).

The communicating branch between the roots of the median nerve has been reported previously by Badawoud (2003). He described the presence of two communicating branches between roots of median nerve. Both ranged from the medial root to the lateral root of the nerve, and likewise in this case, the presence was unilateral with a 2.1% frequency (1 of 48 upper limbs)

According Singhal *et al.* (2007) the anomalous communicating branches that crosses the axillary artery by its anterior view, can cause compression syndromes, producing ischemia. According to Badawoud, the presence of this communicating branch could compress the axillary artery and reduce blood supply to the upper limb.

Due to the frequency with which diagnostic and surgical procedures are performed at the upper limbs, the knowledge of such anatomical variations is important in order to avoid errors in the diagnosis or undesirable consequences.

CERDA, A. Tercera cabeza del músculo bíceps braquial asociada a la comunicación bilateral de los nervios musculocutáneo y mediano y a un ramo comunicante entre las raíces del nervio mediano. Reporte de un caso. *Int. J. Morphol.*, 32(2):510-514, 2014.

RESUMEN: Tanto las variaciones anatómicas del músculo bíceps braquial como la presencia de ramos comunicantes entre los nervios musculocutáneo y mediano son frecuentes y tienen importancia clínica, debido a sus relaciones y vulnerabilidad. Se describe un caso encontrado durante una rutina de disección de los miembros superiores de un cadáver masculino, en el que coexiste la presencia unilateral de una tercera cabeza del músculo bíceps braquial asociada a una comunicación bilateral entre los nervios musculocutáneo y mediano junto a un ramo comunicante unilateral entre las raíces del nervio mediano. Se presentan sus características morfológicas, su prevalencia y se discute su importancia clínica.

PALABRAS CLAVE: Bíceps braquial; Nervio musculocutáneo; Nervio mediano; Plexo braquial; Variaciones anatómicas.

REFERENCES

- Abu-Hijleh, M. F. Three-headed biceps brachii muscle associated with duplicated musculocutaneous nerve. *Clin. Anat.*, 18(5):376-9, 2005.
- Anyanwu, G. E.; Obikili, E. N.; Esom, A. E. & Ozoemana, F. N. Prevalence and pattern of communication of median and musculocutaneous nerves within the black population: Nigeria

- a case study. *Int. J. Biomed. Health Sci.*, 5(2):87-94, 2009.
- Badawoud, M. A study on the anatomical variations of median nerve formation. *Bahrain Med. Bull.*, 25(4):1-5, 2003.
- Balasubramanian, A. Supernumerary head of biceps brachii. *Int. J. Anat. Var.*, 3:214-5, 2010.
- Catli, M. M.; Ozsoy, U.; Kaya, Y.; Hizay, A.; Yildirim, F. B. & Sarikcioglu, L. Four-headed biceps brachii, three-headed coracobrachialis muscles associated with arterial and nervous anomalies in the upper limb. *Anat. Cell Biol.*, 45(2):136-9, 2012.
- Cerda, A. & Suazo Galdames, I. Bilateral Communications of the musculocutaneous and median nerves, morphological aspects and clinical significance. *Int. J. Morphol.*, 30(2):651-5, 2012.
- Choi, D.; Rodríguez-Niedenführ, M.; Vázquez, T.; Parkin, I. & Sañudo, J. R. Patterns of connections between the musculocutaneous and median nerves in the axilla and arm. *Clin. Anat.*, 15(1):11-7, 2002.
- García-Porrero, J. & Hurlé, J. *Anatomía humana*. Madrid, Mc Graw-Hill Interamericana, 2005.
- Goyal, N.; Harjeet & Gupta, M. Bilateral variant contributions in the formation of median nerve. *Surg. Radiol. Anat.*, 27(6):562-5, 2005.
- Ilayperuma, I.; Nanayakkara, G. & Palahepitiya, N. Incidence of humeral head of biceps brachii muscle. Anatomical insight. *Int. J. Morphol.*, 29(1):221-5, 2011.
- Kervancioglu, P. & Orhan, M. An anatomical study on the three-headed biceps brachii in human foetuses, and clinical relevance. *Folia Morphol. (Warsz.)*, 70(2):116-20, 2011.
- Lee, S. E.; Jung, C.; Ahn, K. Y. & Nam, K. I. Bilateral asymmetric supernumerary heads of biceps brachii. *Anat. Cell Biol.*, 44(3):238-40, 2011.
- Loukas, M. & Aqueelah, H. Musculocutaneous and median nerve connections within, proximal and distal to the coracobrachialis muscle. *Folia Morphol. (Warsz.)*, 64(2):101-8, 2005.
- Mas, N.; Pelin, C.; Zagyapan, R. & Bahar, H. Unusual relation of the median nerve with the accessory Head of the biceps brachii muscle: an original case report. *Int. J. Morphol.*, 24(4):561-4, 2006.
- Nayak, S. R.; Prabhu, L. V. & Sivanandan, R. Third head of biceps brachii: A rare occurrence in the Indian population. *Ann. Anat.*, 188(2):159-61, 2006.
- Nayak, S. R.; Krishnamurthy, A.; Kumar, M.; Prabhu, L. V.; Saralaya, V. & Thomas, M. M. Four-headed biceps and triceps brachii muscles, with neurovascular variation. *Anat. Sci. Int.*, 83(2):107-11, 2008.
- Ongeti, K.; Pulei, A.; Ogeng'o, J. & Saidi, H. Unusual formation of the median nerve associated with the third head of biceps brachii. *Clin. Anat.*, 25(8):961-2, 2012.
- Pacholczak, R.; Klimek-Piotrowska, W. & Walocha, J. A. Absence of the musculocutaneous nerve associated with a supernumerary head of biceps brachii: a case report. *Surg. Radiol. Anat.*, 33(6):551-4, 2011.
- Rodríguez-Niedenführ, M.; Vázquez, T.; Choi, D.; Parkin, I. & Sañudo, J. R. Supernumerary humeral heads of the biceps brachii muscle revisited. *Clin. Anat.*, 16(3):197-203, 2003.
- Saeed, M. & Rufai, A. A. Median and musculocutaneous nerves: variant formation and distribution. *Clin. Anat.*, 16(5):453-7, 2003.
- Singhal, S.; Rao, V. V. & Ravindranath, R. Variations in brachial plexus and the relationship of median nerve with the axillary artery: a case report. *J. Brachial Plex. Peripher. Nerve Inj.*, 2:21, 2007.
- Sontakke, Y. A.; Fulzele, R. R.; Tamgire, D. W.; Joshi, M.; Gajbe, U. L. & Marathe, R. R. Unilateral variant origin of musculocutaneous nerve. *Int. J. Anat. Var.*, 3:59-60, 2010.
- Venieratos, D. & Anagnostopoulou, S. Classification of communications between the musculocutaneous and median nerves. *Clin. Anat.*, 11(5):327-31, 1998.
- Vollala, V. R.; Nagabhooshana, S.; Bhat, S. M.; Potu, B. K. & Rakesh, V. Multiple accessory structures in the upper limb of a single cadaver. *Singapore Med. J.*, 49(9):e254-8, 2008.

Correspondence to:
Aladino Cerda Alarcón
Universidad de Talca
Departamento de Ciencias Básicas Biomédicas
Avenida Lircay s/n Oficina N° 1, Talca
CHILE

E-mail: alcerda@utalca.cl

Received: 10-01-2014
Accepted: 14-04-2014