

Sartorial Branch of Saphenous Nerve: Anatomical Relationship with Bony Landmarks and Great Saphenous Vein

Ramo Sartorial del Nervio Safeno Safeno: Relación Anatómica con Puntos de Referencia Óseos y de la vena Safena Magna

Amornrat Tothonglor; Sithiporn Agthong; Thanasil Huanmanop & Vilai Chentanez

TOTHONGLOR, A.; AGTHONG, S.; HUANMANOP, T. & CHENTANEZ, V. Sartorial branch of saphenous nerve: Anatomical relationship with bony landmarks and great saphenous vein. *Int. J. Morphol.*, 31(2):432-437, 2013.

SUMMARY: Sartorial branch of saphenous nerve (medial crural cutaneous nerve) originates at the medial side of the knee and descends along the great saphenous vein (GSV) to innervate the medial aspect of the leg. Its anatomy is of concern in surgical procedures and anesthetic block. However, the measurement data related to palpable bony landmarks with comparison between sexes and sides are lacking. Dissection was done in 95 lower limbs from both sexes. We found that the nerve pierced the deep fascia alone in most cases (92.6%). This piercing point was always distal to the adductor tubercle with the distance of 5-6 cm which was 15% of the leg length (the distance between the adductor tubercle and medial malleolus). The nerve was 7 cm medial to the tibial tuberosity. At the mid-level of leg length, the nerve was slightly over 4 cm medial to the anterior tibial margin. The nerve terminally divided 7 cm proximal to the medial malleolus. Furthermore, the anatomical relationship between the nerve and the GSV was highly variable. The nerve was constantly anterior, posterior or deep to the GSV in 8.4%, 15.8% and 2.1%, respectively. Crossing between the two structures was observed in 57.9% of specimens and the distance to the medial malleolus was 18 cm. Symmetry was found in most parameters and significant gender differences were observed in some distances. These results are important for avoiding the sartorial nerve injury and locating the nerve during relevant procedures.

KEY WORDS: Anatomy; Great saphenous vein; Saphenous nerve; Sartorial branch.

INTRODUCTION

Saphenous nerve is the sensory branch of femoral nerve supplying the medial aspects of the knee, leg and ankle. It generally divides into 2 major branches, infrapatellar and sartorial, piercing deep fascia at the medial side of the knee. The infrapatellar branch courses anterolaterally distal to the patella. The sartorial branch (medial crural cutaneous nerve) descends along the great saphenous vein (GSV) towards the medial aspect of the ankle.

Clinical importance of the sartorial branch is documented. Since the nerve runs closely along the GSV in the leg, its injury has been reported after varicose vein surgery (Holme *et al.*, 1990; Canonico *et al.*, 2000). Moreover, harvesting of the GSV for coronary artery bypass grafting could injure the nerve (Nair *et al.*, 1988). At the ankle, trauma of the sartorial branch due to arthroscopic portal placement has been reported (Ferkel *et al.*, 1996). Blockade of this nerve combined with other nerves has also been done for ankle and foot surgery (Varitimidis *et al.*, 2009).

Therefore, knowledge of the anatomy of the sartorial branch is crucial to successful and safe surgical interventions.

The anatomy of sartorial branch related to tendinous or ligamentous landmarks has been studied (Dunaway *et al.*, 2005; Sanders *et al.*, 2007). More stable and palpable bony landmarks have also been used. The relationship between the point where the nerve becomes superficial (piercing point) and the medial epicondyle of femur was analyzed in 40 legs (Arthornthurasook & Gaew-Im, 1990). Dayan and colleagues located the piercing point using the knee fold and the medial malleolus as landmarks in 20 legs (Dayan *et al.*, 2008). The distances from the sartorial nerve to medial epicondyle and adductor tubercle were measured (Wijdicks *et al.*, 2010). The course of the distal saphenous nerve related to the medial malleolus was also described (Mercer *et al.*, 2011). In addition, the related anatomy of the sartorial branch and the GSV was also reported (Dayan *et al.*; Veverková *et al.*, 2011). However, more details in the anatomical course

of the sartorial branch, especially regarding sexes and sides, are needed for better locating the nerve during surgical procedures.

MATERIAL AND METHOD

Ninety-five lower extremities from 48 formalin-fixed cadavers (31 males and 17 females) were included with an approval from the institutional ethics committee. One left female leg was excluded due to the flexion contracture of knee. The average age of cadavers was 70.5 ± 15.6 years (26-93 years).

The medial aspects of the knee, leg and ankle were carefully dissected to expose the infrapatellar and the sartorial branches including the GSV with their anatomical positions preserved with pins. The most prominent points of the adductor tubercle of femur, the tibial tuberosity and the medial malleolus were identified after removal of overlying skin and soft tissue when necessary for more accurate localization. These landmarks were marked with pins. The course of the sartorial branch from its piercing point at the knee to the terminal branching point at the ankle was followed. This was compared with the anatomy of GSV.

To obtain quantitative data, a digital caliper was used to measure the following distances from the sartorial branch to bony landmarks (Fig.1): distance from the piercing point to the adductor tubercle, distance from the piercing point to the medial malleolus, distance between the nerve and the tibial tuberosity, distance between the nerve and anterior tibial margin at the mid-level of leg length (distance from the adductor tubercle to the medial malleolus), and distance from the terminal branching point to the medial malleolus. Furthermore, the distance from where the nerve crossed the GSV to the medial malleolus was also measured.

Student's t test was carried out to detect any significant differences in the above data between sexes and sides. $p < 0.05$ was considered significant.

RESULTS

The sartorial branch emerged from the deep fascia separately from the infrapatellar branch in most cases (88 specimens, 92.6%) (Fig.2a). In the remaining legs, the saphenous nerve emerged as a single trunk and later bifurcates (Fig.2b). These patterns were similar between sides in the same body in all cases except 2 females and 1 male.

The piercing point of the sartorial branch was posterior to the adductor tubercle in all cases. The mean distances from the piercing point to the adductor tubercle were 1.3 ± 0.7 (SD) cm in male and 1.1 ± 0.7 cm in female (Table I). The piercing point was always distal to the adductor tubercle with the distances of 5.7 ± 1.8 and 5.1 ± 2.1 cm in male and female, respectively. In addition, the piercing point was 31.6 ± 2.5 and 29.0 ± 2.5 cm proximal to the medial malleolus in male and female, respectively. There were significant differences

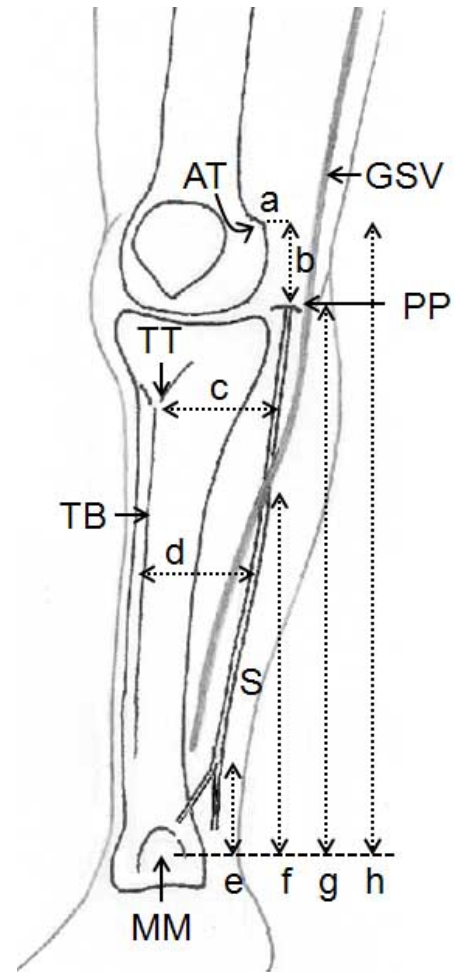


Fig. 1 Measurements regarding the anatomy of the sartorial branch (S) related to various landmarks: adductor tubercle of femur (AT), tibial tuberosity (TT), anterior tibial margin (TB) and medial malleolus (MM) on the right lower limb. a,b distances from the piercing point of nerve (PP) to the AT posteriorly and distally, respectively; c distance from the nerve to the TT; d distance from the nerve to the TB at the mid-level of leg length; e distance from the terminal branching point to the MM; f distance from the crossing point between the nerve and great saphenous vein (GSV) to the MM; g distance from the piercing point to the MM; h distance between the AT and the MM (leg length)

in this measurement between sexes on both sides ($p < 0.01$). These distances from the nerve to the adductor tubercle and the medial malleolus were approximately 15% and 85% of the leg length, respectively, in

Table I Measurement data of the sartorial branch of saphenous nerve

Measurement	Distance (cm) (% of leg length)					
	Male			Female		
	Left	Right	Bilateral	Left	Right	Bilateral
Piercing point to AT - posteriorly	1.3 ± 0.7	1.3 ± 0.7	1.3 ± 0.7	1.0 ± 0.6	1.1 ± 0.7	1.1 ± 0.7
- distally	5.7 ± 1.8 (15.2±4.8%)	5.7 ± 1.7 (15.3±4.6%)	5.7 ± 1.8 (15.3±4.7%)	5.0 ± 2.0 (14.8±6.2%)	5.2 ± 2.1 (14.9±5.9%)	5.1 ± 2.1 (14.9±6.1%)
Piercing point to MM	31.4 ± 2.3 ^a (84.7±5.1%)	31.7 ± 2.7 ^a (85.3±5.0%)	31.6 ± 2.5 (85.0±5.0%)	28.7 ± 2.6 (84.6±7.8%)	29.3 ± 2.4 (85.2±6.3%)	29.0 ± 2.5 (84.7±7.0%)
Nerve to TT	7.4 ± 0.6 ^a	7.3 ± 0.5 ^a	7.4 ± 0.6	6.7 ± 0.7	6.8 ± 0.8	6.8 ± 0.8
Nerve to TB	4.7 ± 0.8 ^b	4.9 ± 0.8	4.8 ± 0.8	4.2 ± 0.7	4.5 ± 0.8	4.4 ± 0.8
TBP to MM	6.7 ± 2.8 (18.2±7.4%)	6.2 ± 2.7 (16.6±7.0%)	6.5 ± 2.8 (17.5±7.2%)	7.1 ± 2.8 (20.8±7.7%)	7.2 ± 3.0 (21.0±9.0%)	7.2 ± 2.9 (21.0±8.3%)
Crossing point to MM	18.3 ± 6.9 (49.7±19.1%)	20.7 ± 7.1 (55.8±17.7%)	18.2 ± 7.4 (52.7±18.5%)	21.3 ± 6.9 (63.7±19.3%)	18.1 ± 6.0 (53.1±16.0%)	18.4 ± 6.4 (57.1±17.5%)
Leg length (AT to MM)	37.1 ± 2.2 ^a	37.1 ± 2.1 ^a	37.1 ± 2.2	34.0 ± 2.1	34.4 ± 2.1	34.2 ± 2.1

Data are means ± SD AT = Adductor tubercle of femur, MM = Medial malleolus, TT = Tibial tuberosity, TB = Anterior tibial margin, TBP = Terminal branching point a p < 0.01 vs. corresponding side of female, b p < 0.05 vs. corresponding side of female.

both sexes. There were no significant differences in the other measurements related to the piercing point between sexes or sides.

The sartorial branch was 7.4 ± 0.6 and 6.8 ± 0.8 cm medial to the tibial tuberosity in male and female, respectively. The differences between sexes were statistically significant on both sides (p < 0.01). At the mid-level of leg length, the distances between the nerve and the anterior tibial margin were 4.8 ± 0.8 and 4.4 ± 0.8 cm in male and female, respectively. A significant difference between sexes was seen only on the left side (p < 0.05).

The sartorial nerve in every case divided into terminal branches proximal to the medial malleolus. The distances

from this point to the medial malleolus were 6.5 ± 2.8 and 7.2 ± 2.9 cm in male and female, respectively. When comparing to the leg length, these distances were approximately 17% in male and 21% in female. The differences between sexes or sides were not significant.

Regarding the relationship with the GSV, the sartorial branch was anterior, posterior or deep to the GSV at the piercing point (48.4%, 28.4% and 23.2% of cases, respectively). Along the courses of the nerve and vein, a constant anatomical relationship was observed in 25 lower limbs (26.3%). The nerve could be anterior, posterior or deep to the vein. In case of inconstant relationship, the most common pattern was the nerve initially locating anterior to the vein and later posterior to it (25 legs, 26.3%). The second

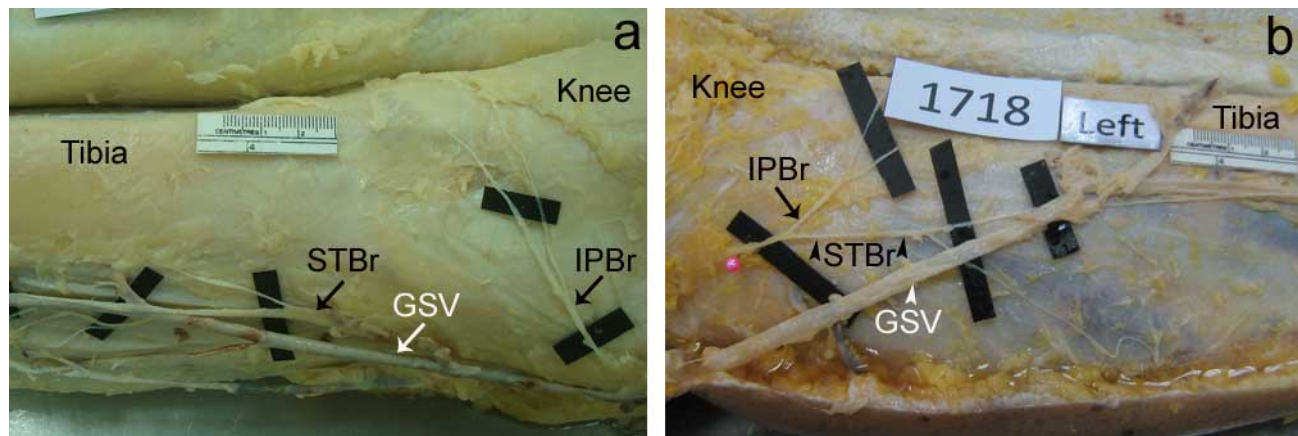


Fig. 2. Patterns of the emergence of sartorial (STBr) and infrapatellar (IPBr) branches of the saphenous nerve: separation of the STBr and the IPBr (a) and single trunk of saphenous nerve (b). GSV Great saphenous vein

most common was the nerve anterior and then deep to the vein (15 legs, 15.8%). These findings were similar between sexes. Symmetry in the relationship patterns between the nerve and vein was observed in 4 males and 7 females (22.9%).

The sartorial branch crossed the GSV in 55 specimens (57.9%) with the nerve deep to the vein in the majority of cases (40 of 55 legs). The distances from the crossing point to the medial malleolus were 18.2 ± 7.4 cm in male and 18.4 ± 6.4 cm in female. These were 52.7% and 57.1% of the leg length in average in male and female, respectively. The differences between sexes or sides were not statistically significant.

DISCUSSION

Our results showed that, in the majority of cases, the sartorial branch emerged from the deep fascia separately from the infrapatellar branch. The piercing point of the sartorial branch was about 1 cm away from the adductor tubercle posteriorly. This point was distal to the adductor tubercle in all specimens with the average distance of 5-6 cm. Furthermore, the piercing point was approximately 30 cm proximal to the medial malleolus. When compared to the leg length, the distance from the piercing point to the adductor tubercle was 15% and that between the piercing point and the medial malleolus was 85%. Dayan and co-workers reported the distance of 32 cm between the piercing point and the medial malleolus which was 89% of the distance between the medial malleolus and knee fold (Dayan *et al.*). Arthornthurasook and Gaew-Im, found that the piercing point was always distal to the medial epicondyle except in one leg. More distally, we found that the distance from the sartorial branch to the tibial tuberosity was about 7 cm. The tibial tuberosity has not been previously used as the landmark for studying the course of sartorial branch.

The anatomy of the sartorial branch at the medial aspect of the knee is important for avoiding the nerve injury in several surgical procedures (Kim *et al.*, 2002). The nerve could be injured during meniscus repair (Austin & Sherman, 1993; DeHaven, 1999). There has been a case report of saphenous nerve trauma following medial knee joint injection (Iizuka *et al.*, 2005). The nerve was also at risk during harvesting of hamstring tendons (Sanders *et al.*). Besides prevention of nerve injury, its anatomy is also crucial for effective anesthetic injection performed at the knee level (Benzon *et al.*, 2005). The results from our study and Dayan *et al.*, suggest that the sartorial branch become superficial

approximately 30 cm proximal to the medial malleolus which is almost 90% of the distance from the medial malleolus to the knee. In addition, the nerve courses approximately 7 cm medial to the tibial tuberosity.

At the mid-level of leg length, we found that the nerve was slightly over 4 cm medial to the anterior tibial margin. This parameter has not been used in the previous studies and no other palpable landmarks at this region have been proposed. Its advantage is the easily palpable anterior tibial margin. However, the leg length (the distance between the adductor tubercle and the medial malleolus) must be determined first. These data can be applied to prevent the nerve trauma in any surgery involving the medial leg, for example, fasciotomy (Pyne *et al.*, 2003).

When the nerve terminally divided, the distance from this point to the medial malleolus was approximately 7 cm (17-21% of leg length). The previous report described a slightly shorter distance of 6 cm (Dayan *et al.*). In contrast, Mercer and co-workers reported a mean distance of 3 cm from 8 cadavers (Mercer *et al.*). The reason of these conflicting data is unknown but could be due to the small number of specimens included in Mercer *et al.* Therefore, the distance was likely 6-7 cm and these data would be useful for successful nerve block at the ankle around the medial malleolus (Benzon *et al.*).

Concerning the relationship with the GSV, our results showed that the sartorial branch was anterior to the GSV at the piercing point in almost half of the cases (48.4%). The less common positions were the nerve posterior or deep to the vein (28.4% and 23.2%, respectively). Dayan and co-workers reported the incidences of 45%, 45% and 10% for the anterior, posterior and deep positions of the nerve relative to the vein at this point (Dayan *et al.*, 2008). We found that the nerve was anterior, posterior or deep to the GSV for its entire course in 8.4%, 15.8% and 2.1% of specimens, respectively. Dayan *et al.*, stated that the nerve was always posterior or deep to the GSV in 40% and 5%, respectively. Therefore, the incidence of constant relationship between the nerve and the GSV in our specimens was 26.3% compared with 45% in Dayan *et al.* As for the crossing between the nerve and the vein, we observed that the crossing occurred in 57.9% of cases with the nerve deep to the vein in the majority of these cases (72.7%). This point was about 18 cm proximal to the medial malleolus (53-57% of the leg length). In contrast, Dayan and colleagues found the crossing in 55% with the nerve superficial to the vein in 90% of cases. They also reported the distance of 23 cm to the medial malleolus which was 63% of the distance between the adductor tubercle and the medial malleolus.

The conflicting data between our and the previous studies indicate that variations in the anatomical relationship between the sartorial nerve and the GSV are high. The nerve could be anterior, posterior or deep to the vein and the constant relationship could be expected in less than half of the cases. The results of another study also supported this view (Veverková *et al.*; Carvallo & del Sol, 2011). One possible explanation for the conflicting results among studies is the different populations used. Our cadavers were Asian, whereas those of Dayan *et al.*, and Veverková *et al.*, were Hispanic and Caucasian, respectively. Knowledge of the anatomical relationship between these two structures is important because venous procedures, such as vein stripping and harvesting of venous graft for coronary bypass surgery, could injure the nerve (Nair *et al.*, 1988; Holme *et al.*; Mountney & Wilkinson, 1999; Canonico *et al.*, 2000). Therefore, special precaution is required for avoiding the injury of sartorial branch during these procedures as the nerve-vein relationship is highly variable.

As for side-to-side differences, symmetry was observed in most parameters in this study except the anatomical relationship between the nerve and the GSV. In this parameter, symmetry was found in only 11 cadavers (22.9%). Dayan *et al.*, also found no differences between sides. In contrast, significant sex differences were observed in the distances between the piercing point and the medial malleolus, the nerve and the tibial tuberosity including that

between the nerve and the anterior tibial margin. Dayan and colleagues similarly reported the sex difference in the distance between the nerve and the GSV resulting from the different thickness of the adipose layer (Dayan *et al.*). Despite with statistical significance, these differences were relatively small resulting in the limited clinical application.

In conclusion, we reported the anatomy of the sartorial branch of saphenous nerve related to palpable bony landmarks. The distances to the tibial tuberosity, anterior tibial margin and percentage of leg length, were also included. Differences in these parameters between sexes, but not sides, were detected. Furthermore, a highly variable anatomy of the sartorial nerve related to the great saphenous vein was observed. These data would be useful for avoiding nerve injury and locating the nerve during relevant procedures.

ACKNOWLEDGEMENTS

The authors would like to thank Dr. Krit Ratanakit, Dr. Pichet Rungsirisanrat, Dr. Jitpat Tanomteeranun and staffs in the Cadaver Unit, Department of Anatomy, Faculty of Medicine, Chulalongkorn University, for their assistance during the dissection.

TOTHONGLOR, A.; AGTHONG, S.; HUANMANOP, T. & CHENTANEZ, V. Ramo sartorial del nervio safeno: Relación anatómica con puntos de referencia óseos y de la vena safena magna. *Int. J. Morphol.*, 31(2):432-437, 2013.

RESUMEN: El ramo sartorial del nervio safeno (nervio cutáneo medial de la pierna) se origina en el lado medial de la rodilla y desciende a lo largo de la vena safena magna (VSM) para inervar la cara medial de la pierna. Su anatomía es motivo de preocupación en los procedimientos quirúrgicos y en el bloqueo anestésico. Sin embargo, los datos de medición relacionados con puntos de referencia óseos palpables y la comparación entre los lados y en ambos sexos son escasas. Se realizó la disección en 95 miembros inferiores de ambos sexos. Se encontró que el nervio perforó la fascia profunda en la mayoría de los casos (92,6%). Esta punta de perforación fue siempre distal al tubérculo del músculo aductor magno a una distancia de 5-6 cm, que representaba el 15% del largo de la pierna (la distancia entre el tubérculo del aductor magno y el maléolo medial). El nervio se localizaba 7 cm medial a la tuberosidad tibial. Al nivel del tercio medio en ambas piernas, el nervio estaba a una distancia un poco mayor a 4 cm medial al margen anterior de la tibia. El nervio se dividía 7 cm proximal al maléolo medial. Por otra parte, la relación anatómica entre el nervio y la VSM fue muy variable. El nervio era constantemente anterior, posterior o profundo a la VSM en 8,4%, 15,8% y 2,1%, respectivamente. Cruce entre las dos estructuras anatómicas se observó en el 57,9% de las muestras y la distancia hasta el maléolo medial fue de 18 cm. La simetría se encuentra en la mayoría de los parámetros y diferencias de sexo significativas se observaron en algunas distancias. Estos resultados son importantes para evitar la lesión del nervio sartorial y localizar el nervio durante los procedimientos pertinentes.

PALABRAS CLAVE: Anatomía; vena safena magna; Nervio safeno; Rama sartorial

REFERENCES

- Arthornthurasook, A.; Gaew-Im, K. The sartorial nerve: its relationship to the medial aspect of the knee. *Am. J. Sports Med.*, 18:41-2, 1990.
- Austin, K. S. & Sherman, O. H. Complications of arthroscopic meniscal repair. *Am. J. Sports Med.*, 21:864-8, 1993.

- Benzon, H.T.; Sharma, S. & Calimaran, A. Comparison of the different approaches to saphenous nerve block. *Anesthesiology*, 102:633-8, 2005.
- Canonica, S.; Luminello, F.; Mainelli, R.; Canonico, R. & Campitiello, F. Long-term recurrence and nerve injury after total and partial stripping of the great saphenous vein by external phleboextractor. *Vasc. Endovascular Surg.*, 34:163-6, 2000.
- Carvalho, E. & del Sol, M. Anatomical relations of the saphenous magna vein with saphenous nerve at the talocrural level. *Int J. Morphol.*, 29 (3):978-981, 2011.
- Dayan, V.; Cura, L.; Cubas, S. & Carriquiry, G. Surgical anatomy of the saphenous nerve. *Ann. Thorac. Surg.*, 85:896-900, 2008.
- DeHaven, K.E. Meniscus repair. *Am. J. Sports Med.*, 27:242-50, 1999.
- Dunaway, D. J.; Steensen, R. N.; Wiand, W. & Dopirak, R. M. The sartorial branch of the saphenous nerve: its anatomy at the joint line of the knee. *Arthrosc.*, 21:547-51, 2005.
- Ferkel, R. D.; Heath, D. D. & Guhl, J.F. Neurological complications of ankle arthroscopy. *Arthroscopy*, 12:200-8, 1996.
- Holme, J. B.; Skajaa, K. & Holme, K. Incidence of lesions of the saphenous nerve after partial or complete stripping of the long saphenous vein. *Acta Chir. Scand.*, 156:145-8, 1990.
- Iizuka, M.; Yao, R. & Wainapel, S. Saphenous nerve injury following medial knee joint injection: a case report. *Arch. Phys. Med. Rehabil.*, 86:2062-5, 2005.
- Kim, T.K.; Savino, R.M.; McFarland, E.G.; Cosgarea, A.J. Neurovascular complications of knee arthroscopy. *Am J Sports Med.*, 30:619-29, 2002.
- Mercer, D.; Morrell, N.T.; Fitzpatrick, J.; Silva, S.; Child, Z.; Miller, R. & DeCoster, T.A. The course of the distal saphenous nerve: a cadaveric investigation and clinical implications. *Iowa Orthop. J.*, 31:231-5, 2011.
- Mountney, J. & Wilkinson, G.A. Saphenous neuralgia after coronary artery bypass grafting. *Eur. J. Cardiothorac. Surg.*, 16:440-3, 1999.
- Nair, U. R.; Griffiths, G. & Lawson, R.A.M. Post-operative neuralgia in the leg after saphenous vein coronary artery bypass graft: a prospective study. *Thorax.*, 43:41-3, 1988.
- Pyne, D.; Jawad, A. S. M. & Padhiar, N. Saphenous nerve injury after fasciotomy for compartment syndrome. *Br. J. Sports Med.*, 37:541-2, 2003.
- Sanders, B.; Rolf, R.; McClelland, W.; Xerogeanes, J. Prevalence of saphenous nerve injury after autogenous hamstring harvest: an anatomic and clinical study of sartorial branch injury. *Arthrosc.*, 23:956-963, 2007.
- Varitimidis, S. E.; Venouziou, A. I.; Dailiana, Z. H.; Christou, D.; Dimitroulias, A. & Malizos, K.N. Triple nerve block at the knee for foot and ankle surgery performed by the surgeon: difficulties and efficiency. *Foot Ankle Int.*, 30:854-9, 2009.
- Veverková, L.; Jedlicka, V.; Vlcek, P. & Kalac, J. The anatomical relationship between the saphenous nerve and the great saphenous vein. *Phlebology.*, 26:114-8, 2011.
- Wijdicks, C. A.; Westerhaus, B. D.; Brand, E. J.; Johansen, S.; Engebretsen, L. & LaPrade, R.F. Sartorial branch of the saphenous nerve in relation to a medial knee ligament repair or reconstruction. *Knee Surg. Sports Traumatol. Arthrosc.*, 18:1105-9, 2010.

Corresponding author
Dr. Sithiporn Agthong
Department of Anatomy
Faculty of Medicine
Chulalongkorn University
Rama IV Road
Pathumwan
Bangkok
10330
THAILAND

Tel. 0662-2564281
Fax 0662-2527028

E-mail: sagthong@hotmail.com

Received: 20-11-2012
Accepted: 25-02-2013