

Looped External Iliac Artery – a Case Report

Arteria Iliaca Externa en Bucle – Reporte de Caso

Satheesha Nayak B.; Naveen Kumar; Surekha D. Shetty & Anitha Guru

NAYAK, B. S.; KUMAR, N.; SHETTY, S. D. & GURU, A. Looped external iliac artery – a case report. *Int. J. Morphol.*, 30(3):870-871, 2012.

SUMMARY: Variations of the external iliac artery are very rare. We found a rare variation in the left external iliac artery. The artery was long and formed a characteristic loop. The loop was found in the lesser pelvis in close relation to the obturator nerve. This loop may compress obturator nerve and vessels. The knowledge of this loop might be important for gynaecologists, orthopaedic surgeons and urologists since it may be involved in surgeries of hip, ovary and prostate.

KEY WORDS: External iliac artery; Anatomical variation; Loop.

INTRODUCTION

The external iliac artery is the larger terminal branch of the common iliac artery. It runs down in the iliac fossa and leaves the pelvis by passing deep to the inguinal ligament. It continues as femoral artery as it crosses the midinguinal point. It is accompanied by the external iliac vein on its medial side. The external iliac artery normally gives two named branches; the inferior epigastric and the deep circumflex iliac arteries. In addition to the above two branches, it gives small branches to psoas major muscle and neighbouring lymph nodes.

CASE REPORT

During routine dissections for medical undergraduate students, we found an abnormal loop of left external iliac artery in a male cadaver aged approximately 60-65 years. The variation was unilateral. The external iliac artery was large and it ran down along the brim of the pelvis initially, and then descended down into the lesser pelvis to form the loop. After reaching the level of obturator nerve, it climbed back to the brim of the pelvis and continued to the thigh behind the inguinal ligament as the femoral artery (Fig. 1). Its normal branches, namely the deep circumflex iliac and inferior epigastric arteries originated from it just above the inguinal ligament (Fig. 1).

DISCUSSION

Variations of external iliac artery are very rare. The artery may be longer or shorter than its normal length. When it is longer, it will be tortuous. The artery may directly originate from aorta (Mansfield & Howard, 2005). It may be much smaller in diameter when the femoral artery arises from the inferior gluteal artery or internal iliac artery. In such cases, the external iliac artery ends in the profunda femoris artery. Occasionally the obturator artery, superficial external pudendal artery or profunda femoris artery may arise from external iliac artery as its abnormal branch (Bergman *et al.*, 1988). Origin of obturator artery from external iliac and the inferior epigastric from femoral artery have been reported by Sarikcioglu & Sindel (2002). Bilgic & Sahin (1997) have found a common trunk arising from external iliac and dividing into obturator, inferior epigastric and profunda femoris arteries. A loop of external iliac artery into the lesser pelvis has been observed by von Hochstetter (1989). Such loop is said to cause complications in total hip replacement surgeries. Tortuosity of the artery may cause complications in radical prostatectomy if its loop is too large. A case of such an abnormally large loop has been reported by Moul *et al.* (1993).

The type of loop of external iliac artery that we are reporting here may be of special interest to urologists, gynaecologists and orthopaedic surgeons. The loop might compress the obturator nerve and vessels and cause related

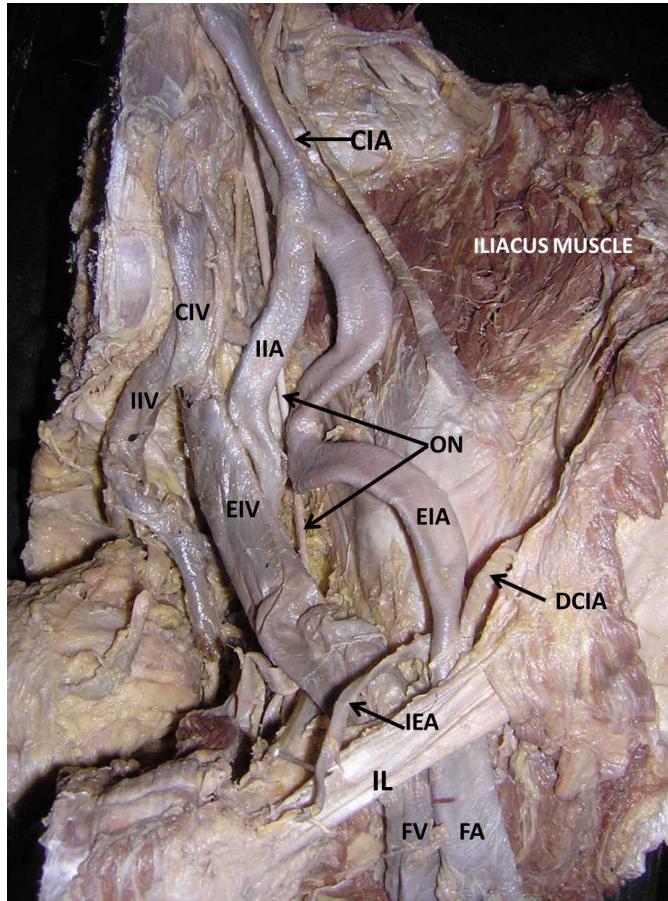


Figure 1. Photograph of dissection of the left iliac vessels. CIA – common iliac artery; EIA – external iliac artery; IIL – internal iliac artery; FA – femoral artery; DCIA – deep circumflex iliac artery; IEA – inferior epigastric artery; CIV – common iliac vein; EIV – external iliac vein; IIV – internal iliac vein; FV – femoral vein; ON – obturator nerve; IL – inguinal ligament.

neurovascular symptoms. Since the loop is directly related to the inner aspect of acetabulum, it may be endangered in total hip replacement surgeries. In females, the loop might compress the fallopian tube or ovary and cause complications in transfer of gametes or might bleed in surgeries of ovary. Even the vascular dynamics may be altered in such a tortuous artery and lower limb may suffer with lack of proper blood supply if the loop of artery is compressed by any of the pelvic viscera.

NAYAK, B. S.; KUMAR, N.; SHETTY, S. D. & GURU, A. Arteria ilíaca externa en bucle – reporte de caso. *Int. J. Morphol.*, 30(3):870-871, 2012.

RESUMEN: Las variaciones de la arteria ilíaca externa son raras. Se encontró una variación poco frecuente en la arteria ilíaca externa izquierda. La arteria era larga y formaba un bucle característico. El bucle se encontró en la pelvis menor en estrecha relación con el

nervio obturador. Este circuito puede comprimir el nervio obturador y los vasos circundantes. El conocimiento de este circuito podría ser importante para los ginecólogos, cirujanos ortopédicos y urólogos, ya que pueden estar involucrados en las cirugías de cadera, ovario y próstata.

PALABRAS CLAVE: Arteria ilíaca externa; Variación anatómica; Bucle.

REFERENCES

- Bergman, R. A.; Thompson, S. A.; Afifi, A. K. & Saadeh, F. A. *Compendium of Human Anatomic variation: Catalog, Atlas and World Literature*. Baltimore and Munich, Urban and Schwazenberg, 1988.
- Bilgic, S. & Sahin, B. Rare arterial variation: a common trunk from the external iliac artery for the obturator, inferior epigastric and profunda femoris arteries. *Surg. Radiol. Anat.*, 19(1):45-7, 1997.
- Mansfield, A. O. & Howard, J. M. Absence of both common iliac arteries. A case report. *Anat. Rec.*, 150:363-4, 2005.
- Moul, J. W.; Wind, G. G. & Wright, C. R. Tortuous and aberrant external iliac artery precluding radical retropubic prostatectomy for prostate cancer. *Urology*, 42(4):450-2, 1993.
- Sarikcioglu, L. & Sindel, M. Multiple vessel variations in the retropubic region. *Folia Morphol. (Warsz)*, 61(1):43-5, 2002.
- von Hochstetter, A. H. The “lesser pelvic loop” of the external iliac artery. *Surg. Radiol. Anat.*, 11(1):23-7, 1989.

Correspondence to:

Dr. Satheesha Nayak B.
Professor and Head, Department of Anatomy
Melaka Manipal Medical College (Manipal Campus)
International Centre for Health Sciences
Manipal University
Madhav Nagar
Manipal, Udipi District
Karnataka State 576 104
INDIA

Telephone: +91 820 2922519
+91 9844009059
Fax: +91 820 2571905

Email: nayaksathish@yahoo.com

Received: 28-05-2011
Accepted: 23-03-2012